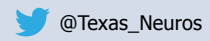





# Broca's Area

The Voice of Texas Neurology



Eddie Patton Jr., MD  
TNS President

If I had to sum up my year as president of the Texas Neurological Society into one word, that word would be grateful. First, I'm grateful for this organization and all that it has provided for me since my residency. Second, I'm grateful for the members I have learned and fellowshiped. I am also very grateful to my fellow board members. Finally, I am grateful to my family for understanding the importance of TNS and the service we provide for our members and neurologists in the state. Through numerous conversations and debates, I have become a better leader. I have a much more profound respect and understanding of the importance of organized medicine.

This year I wanted to shine a

## President's Message

light on the practice of medicine, specifically neurology, and help physicians learn and understand some of the nuances dealing with the business of medicine. Understanding the art of healing, the science of medicine, and the business of healthcare is essential. If we understand all three of these facets and learn to use them to impact how we treat patients positively, we are showing others that we are not "providers" but leaders of healthcare. We must transition from being reactive to being proactive. We can continue to protect its most sacred entity, the patient /physician relationship. I was not trained well during my residency in the business of medical practice, and I know many other members who expressed this sentiment. The Texas Neurological Society realized and acknowledged this deficit in understanding and decided to do something about it. I am proud of the work we have been doing with the Medical Economics section and the "Business of Neurology" video series. Through this series, members of this organization hear from real experts on navigating the

maze of running a practice.

As an organization, we successfully traversed one of the worst public health crises in history, the COVID-19 pandemic. TNS is strong financially and strong in its membership. We have a strong relationship as a leading state neurological society throughout this country. This would not be the case if it weren't for our solid administrative support and a board that works hard to make sure that Texas is the best state in the nation to receive neurological care. This was not without sacrifice and hard decisions. For a while, we transition to virtual conferences. Then, hybrid meetings. And now we are back to having our conferences live and in person. It took strong leadership from our administration, past presidents, and board to pull this off and grow as an organization.

I appreciate the opportunity to serve as president of this great organization. I look forward to continuing to serve TNS because TNS has served me. It has provided tremendous educational value for me over the years.

It has provided a platform for advocacy to continue fighting for neurology and the patients we care for. It has provided an opportunity for me to give back to the community, and it has provided a way for me to make friends from all over the state of Texas. I love President Kennedy's quote, "Ask not what your country can do for you – ask what you can do for your country," and I try to apply this to many aspects of my professional and personal life.

In closing, I would say, "Ask not what TNS can do for you- but what you can do for TNS." If we work together, we can improve the neurological workforce in our state. We can continue to improve the neurological care that patients receive. We cannot sit back and let our future be determined for us. We must actively participate in shaping the house of medicine moving forward. Thank you for supporting the Texas Neurological Society, and let's continue to ensure that Texas is the gold standard for neurological care.

**CONTENTS**

***TNS Brocas is digital and interactive***  
Open this newsletter in Firefox or Google Chrome for the best experience.

[EDITOR'S NOTES](#)


[TNS LEGISLATIVE UPDATE](#)

[TNS LEGISLATIVE DAY](#)

[ARTICLES](#)

[MEMBER NEWS](#)

[CASE STUDIES](#)



## Editor's Notes

Randolph W. Evans, MD

### THIS ISSUE

*I thank our officers and other contributors for their excellent submissions to this issue. We look forward to seeing you at the TNS 26<sup>th</sup> Annual*

*Winter Conference at the Hyatt Regency Austin. Shivika Chandra, program director, Erin Furr-Stimming, committee chair, and the education committee have planned an excellent program.*

### HISTORIÈS

You vaguely remember the Greek Herodotus (c. 485-425 BC) who used the word “historiēs”, Greek for “inquiry,” in the first sentence of the first-ever work of history, “The Histories,” recounting the war between the Greeks and Persians (Le B. The Histories of Herodotus in Greek: Introductory Paragraph, Part I. Winds & Waves. December 24, 2013). He has the earliest recounts of the still famous running Athenian hoplites at the Battle of Marathon (490 BC) and the last stand of the Spartans at the Battle of Thermopylae (480 BC) (DeSantis MG. Who was Herodotus? LiveScience. March 2, 2022).

According to Herodotus, Pheidippides ran 140 miles from Athens to Sparta to ask for aid before the Battle of Marathon. Herodotus did not describe a 25-mile run from Marathon to Athens to announce the Greek victory upon which he died from exhaustion. This was a later myth which was revived for the first modern Olympics in 1896 in Athens.

While Cicero named Herodotus the “father of history,” Plutarch called him the “father of lies (for being partial).” There were many inaccuracies in his text.

We are perhaps the premier historians in medicine. Our histories or inquiries are among the longest. For many disorders and diseases, we diagnose from the history and not from the exam or testing. This is the lesson we try to impart to trainees that diagnostic testing is not a substitute for an inadequate history.

Unfortunately, in many instances, we can only be as accurate as the information provided to us. Many of my patients become impatient or upset with my history taking which some have compared to being interrogated by a police detective. We try to explain that as disease detectives we have a similar job to be as thorough as we can.

We also do physicals, another word from ancient Greek, “phusikē,” knowledge of nature. Thomas Willis of course, invented the term



*This bronze helmet was likely worn by a soldier fighting in the Greek-Persian wars. (Image credit: Israel Antiquities Authority) (Jarus O. Ancient helmet worn by soldier in the Greek-Persian wars found in Israel. Live Science March, 2, 2022).*

“neurologia” in his 1664 book, “Cerebri Anatome” (Caron L. Thomas Willis, the Restoration and the First Works of Neurology. Med Hist. 2015 Oct;59(4):525-53). Willis wrote in Latin but derived the term from ancient Greek meaning “the doctrine of the nerves (ology was used body of knowledge such as astrology or theology).”

So our histories and physicals are inquiries and knowledge of nature.

### AIRPLANE HEADACHE

This is a 53 year old female with headaches occurring every time when she flew about twice a year first in 2007 and last 2019. The headache onset was always upon descent about 10-15 minutes before landing described as a bifrontal jabbing or needles then something moving through the brain stabbing with an intensity of 10/10 associated with nausea, diaphoresis, lightheadedness but no vomiting. She can't recall if light or nose sensitivity was present. Stopped up ears no longer occurred since getting tubes in her ears in 2014 to treat the headache but did not help the headaches. The pain would go away immediately upon landing.

There was no history of other headaches.

She saw several ENT physicians including a neuro-otologist. She was examined by an ENT right after the flight and had no sinus or nasal congestion. An audiogram reportedly showed bilateral SNHL since 2011. Multiple MRI scans of the brain and CT scans of the sinuses were reportedly negative. She also saw a neurosurgeon who obtained another MRI of the brain with no suggestions.

Nasal decongestants, pseudoephedrine, ibuprofen, acetaminophen, diclofenac-lidocaine cream, and chewing gum on descent did not help. She took alprazolam and cyclobenzaprine before her last flight and the pain was 50% less.

### Questions?

What is the diagnosis? Are there any other medications which might be of benefit?

Airplane headache (AH) was first reported in 2004 in a single case (Atkinson V, Lee L. An unusual case of an airplane headache. Headache. 2004;44:438-489). Our 3 patients were the third publication (Evans RW, Purdy RA, Goodman SH. Airplane descent headaches. Headache. 2007;47:719-723). Since then, there have been many case studies and surveys.

AH is defined by the ICHD3 as follows (Headache Classification Committee of the International Headache Society (IHS), The International Classification of Headache Disorders, 3rd edition, Cephalalgia 2018; 38(1):1-211):

“Headache attributed to aeroplane travel

### Description:

Headache, often severe, usually unilateral and periorbital and without autonomic symptoms, occurring during and caused by aeroplane travel. It remits after landing.

### Diagnostic criteria:

- A. At least two episodes of headache fulfilling criterion C
- B. The patient is travelling by aeroplane
- C. Evidence of causation demonstrated by at least two of the following:
  1. headache has developed during the aeroplane flight
  2. either or both of the following:

## Editor's Notes (continued)

a) headache has worsened in temporal relation to ascent following take-off and/or descent prior to landing of the aeroplane

b) headache has spontaneously improved within 30 minutes after the ascent or descent of the aeroplane is completed

3. headache is severe, with at least two of the following three characteristics:

a) unilateral location

b) orbitofrontal location

c) jabbing or stabbing quality

Not better accounted for by another ICHD-3 diagnosis<sup>4</sup>.

**Notes:**

1. Side-shift between different flights occurs in around 10% of cases.

2. Parietal spread may occur.

3. Pulsation (throbbing) may also be noted.

4. In particular, sinus disorder should be "excluded"

**Comments:** A recent Scandinavian survey has indicated that up to 8.3% of air-travellers experience 10.1.2 Headache attributed to aeroplane travel. It occurs during landing in more than 90% of cases.

Accompanying symptoms are reported in up to 30% of cases. Most frequent are restlessness and unilateral tearing; other localized parasympathetic symptoms, nausea or photo/phonophobia have been described in fewer than 5% of cases.

A proportion of subjects experiencing 10.1.2 Headache attributed to aeroplane travel report similar headache during free snorkeling and/or rapid descent from mountains, suggesting these headaches are due to imbalance between intrasinus and external air pressures.

**Epidemiology and diagnostic criteria.** Although prior studies have found AH in up to 8.3% of air travelers, a recent study of 50,000 disembarking passengers at 2 German international airports found headaches during travel reported by 0.75%. Of

the 374 passengers who underwent a structured interview, 0.2% met the diagnostic criteria of AH. The onset (79.2%), duration (82.2%), and location (73.3%) were mostly similar to ICHD-3 criteria but pain intensity (42.6%) and quality (42.6%) were less in agreement (Konrad F, Moritz A, Moritz M, Keunecke JG, Tischler F, Pröttengeier J. The epidemiology of airplane headache: A cross-sectional study on point prevalence and characteristics in 50,000 travelers. *Cephalalgia*. 2022 Sep;42(10):1050-1057).

The authors concluded, "Currently, there are no proven pathophysiological mechanisms or anatomical correlations for the development of AH. Any localization from the forehead to the occiput, left and right, and uni- and bilateral should be considered as compatible with AH. ... We propose classifying headaches with typical timing and clinical appearance, but not of severe intensity, as AH."

**Treatment.** Pretreatment with simple analgesics, NSAIDs, triptans, and decongestant nasal spray have all been tried with variable success. Ipekdal et al reported 5 patients who had failed NSAIDs who took various oral triptan 30-45 minutes before travel resulting in prevention of the headache (Ilker Ipekdal H, Karadas O, Oz O, Ulas UH. Can triptans safely be used for airplane headache? *Neurol Sci*. 2011;32(6):1165-9). Applying pressure to the painful area, Valsalva maneuver, relaxation methods, chewing, and extension of the earlobes have not been helpful (Nierenburg H, Jackfert K. Headache Attributed to Airplane Travel: A Review of Literature. *Curr Pain Headache Rep*. 2018 Jun 14;22(7):48).

**This case.** I saw her for the only time in April, 2022 and recommended that she take rizatriptan 10 mg 30 minutes before the take off if the flight was 2 hours or more and a 2nd dose (or only dose if the flight was less than 2 hours) 1 hour before landing (Delva I, Delva M. Successful Treatment of Airplane Headache with Rizatriptan: Case Report. *Case Rep Neurol*. 2021 Jun 14;13(2):375-379).


She called back a few months later and left a message that she had flown several times since without a headache when taking rizatriptan as directed.



# TNS 2023 Annual Winter Conference

February 3-5 | Hyatt Regency Austin | Austin TX





# Resident Poster *competition*

## TNS invites residents to participate in the Annual Poster Competition.

Prizes will be awarded for 1st, 2nd, and 3rd place in the amounts of \$1000, \$500 and \$250.

### Application Procedures & General Rules:

**TNS Membership:** Neurology Residents and Fellows must be members of TNS (or submit an application)

**Registration:** All participants must register for the TNS 2023 Winter Conference by January 11, 2023.

### Posters should include:


- **Title:** Simple title representing the key element(s) of the study, in very large font
- **Authors:** Write authors full names with middle initials in large font. Indicate each author's highest degree (e.g., Ph.D., M.D.). A comma should be used to separate authors.
- **Affiliations:** Complete names and locations of the institutions where the work was done.
- **Main body:** Use large text and legible figures to describe the work. Use standard scientific outline with headings for Background, Methods, Results and Discussion/Conclusions.
- **References:** References should be cited parenthetically in the text by author and year of publication, for example (Fisher et al., 2011). Limit of 3 references per poster.
- One presentation per resident per competition

*TNS will print all posters at the cost of \$25 per entry to be collected when registering for the conference.*

Applications can be found on the [TNS website](#).

### Follow Us on Social Media!

 @texas\_neuros

 @TexasNeuros

Use hashtag #TNSW2023





## TNS Legislative Update

*Dr. Sara Austin, TNS Legislative Affairs Chair and Tom Holloway, TNS Lead Lobbyist*

The TNS Legislative Affairs Committee is gearing up for the upcoming legislative session beginning in January 2023. As usual, we have a number of old issues that have yet to be resolved, some old issues that will probably never be resolved, and some new issues that we're working through.

### IMPROVING STROKE CARE IN TEXAS

Stroke represents the fifth leading cause of death and one of the leading causes of disability in the United States. As neurologists know so well, rapid treatment is paramount. This session, TNS is working with Memorial Hermann Health System to expand their existing MSU pilot program and fund additional Mobile Stroke Units at Level 1 stroke facilities in Texas. With a record \$27 billion budget surplus heading into the legislative session, there's reason to feel optimistic about the prospects of securing new funding to trial this innovative approach to stroke care in communities across the state.

### SEIZURE ACTION PLANS IN TEXAS SCHOOLS

It is estimated that over 49,000 Texas children have active epilepsy, making it one of the most common brain disorders among adolescents. For those children afflicted by epilepsy, it's critical that the appropriate measures are taken to keep them safe in school. In 2021, the Texas Legislature passed HB 684, (also known as "Sam's Law") which requires all Texas public school personnel whose duties include regular contact with students to be trained in seizure recognition and seizure first aid.

This session, TNS is partnering with the Epilepsy Foundation of Texas to build on the success of HB 684 by developing a standardized Seizure Action Plan for all Texas schoolchildren diagnosed with epilepsy. The plan will clearly describe the type and frequency of seizures the child has, proper first aid care for that specific child, any anti-epileptic medications and emergency medications the child may take, and other important information like contact information for the child's neurologist.

### REDEFINING BRAIN DEATH

This session, several pro-life advocacy groups appear poised to make a renewed run at challenging the end-of-life care protocols established by Texas hospitals and working to redefine the clinical definition of brain death. In response, the Texas Medical Association has assembled a task force of physician experts, led by TNS' own Dr. Yvonne Kew, to advise lawmakers in the development of scientifically sound and medically appropriate guidelines for the determination of brain death in patients.

Achieving the correct balance on this issue is critical for physicians in Texas. On one hand, we want to preserve patient autonomy and the protect the sanctity of the patient-physician relationship. On the other hand, getting the correct diagnosis of brain death is so important because mistakes, however uncommon, clearly undermine people's faith in the process.

At this early stage, we have little more than rumors to operate on

since legislation has yet to be filed. Nonetheless, the TNS legislative team will continue to monitor all new developments and make sure that neurology remains front and center in any legislative efforts to interfere in the independent medical diagnosis of brain death.

### POTENTIAL CHANGES TO MEDICAL CANNABIS

As we approach the next legislative session, lawmakers continue to explore ways of altering or expanding the state's limited medical cannabis program, known as the Texas Compassionate Use Program (TCUP). Last session, the legislature expanded the program's list of qualifying medical conditions, which now include epilepsy, seizure disorders, multiple sclerosis (MS), spasticity, amyotrophic lateral sclerosis (ALS), autism, cancer, incurable neurodegenerative disease, and post-traumatic stress disorder (PTSD).

Despite these changes, the TCUP program remains functionally hindered by a lack of licensed cannabis providers in the state. With only two actively licensed medical cannabis dispensaries in Texas (both in the Austin area) and the law preventing off-site storage, accessing medical cannabis can be extremely difficult, even for patients with a valid prescription. We continue to work with Governor Abbott's office and the Texas Department of Public Safety (the agency that currently oversees the program) to allow additional licenses in other parts of the state.

Moving forward, legislative leaders and advocacy groups appear to be forming consensus around pursuing two modest and specific changes to the TCUP program in 2023: (1) the addition of chronic pain to the list of qualifying conditions, which was removed from the final version of HB 1535 last session, and (2) raising the current limitation of 1% THC by weight, or perhaps changing to a more practical limitation on total dosage.

The TNS Medical Cannabis Task Force, led by Dr. Reeta Achari, has continued to meet regularly throughout the interim to influence the public policy debate surrounding the use of medical cannabis in Texas and ensure that any changes to the Texas Compassionate Use Program (TCUP) are medically sound and in keeping with the appropriate standard of care.

### THE FIRST TNS LEGISLATIVE ADVOCACY DAY

On Tuesday, April 4, 2023, the Texas Neurology Society will hold its first ever Legislative Advocacy Day at the Texas Capitol in Austin. The event will be held in conjunction with the Texas Medical Association's "First Tuesday" event in April (please wear your white coat!) and will give Texas neurologists a unique opportunity to meet with lawmakers face-to-face and discuss the policy issues that matter most to your practice and your patients.

We'd love to make this a successful biennial event, so we encourage all TNS members to please make plans to join us in Austin on April 4. For more details or to sign up for TNS Legislative Advocacy Day, please contact TNS Executive Director Ky Camero at [ky.camero@texmed.org](mailto:ky.camero@texmed.org). We'll see you in Austin!





# TNS LEGISLATIVE DAY

## APRIL 4, 2023

*In conjunction with TMA First Tuesdays*

The Texas Legislature only meets for 140 days every two years... so now is your chance to be heard!

Please join us at the Texas Capitol on Tuesday, April 4 to meet with fellow neurologists from across the state and speak with lawmakers about the issues that impact your practice and your patients.

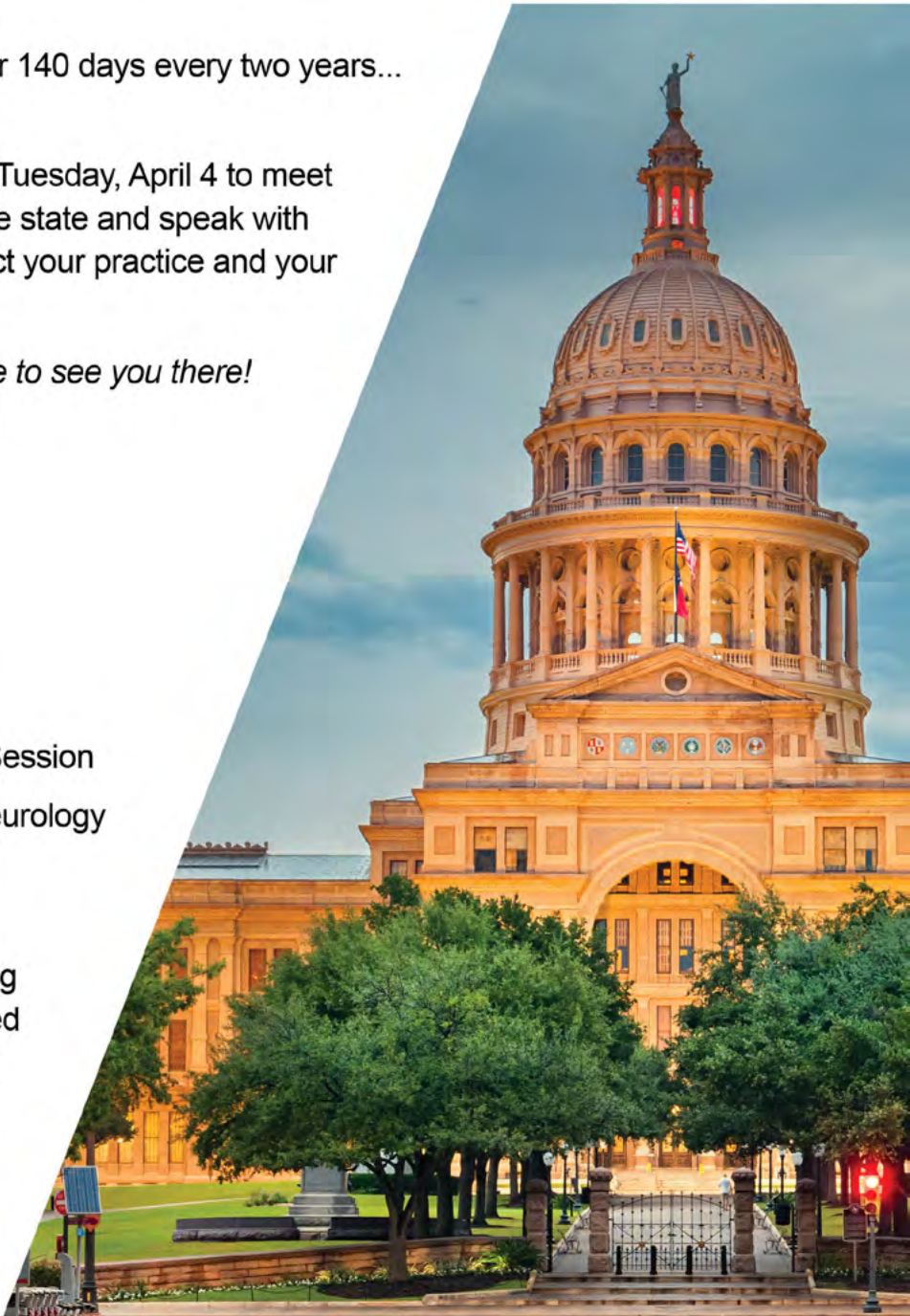*Our voice is louder together and I hope to see you there!*

**Sara Austin, MD**  
TNS Legislative Chair

### AGENDA

*(subject to change)*

- 7:30am** Attend TMA First Tuesday Session
- 8:30am** TNS members gather for neurology issues
- 9am** Go to capitol
- 10am** *(tentative)* Resolution honoring Texas neurologists presented in the Senate and House of Representatives



**TNS Lobbyist - Tom Holloway**  
[tom@crossoakgroup.com](mailto:tom@crossoakgroup.com)

Register today at  
[texmed.org/FirstTuesdays](http://texmed.org/FirstTuesdays)



## AAN Advocacy Focuses on Prior Authorization Process: How You Can Help Now

By: Orly Avitzur, MD, MBA, FAAN - President, AAN

Some of the most frustrating complaints I have heard voiced by neurologists and patients alike over the years are related to enduring the prior authorization (PA) process used by insurers to evaluate whether care is medically necessary and covered. Physicians, who average 41 such reviews a week — translating to almost two business days of physician and staff time according to a 2021 AMA survey, say it is a waste of time and inefficient use of health care dollars. Patients, who end up waiting to attain health care services such as imaging or to take prescribed medication, complain that delays in their care are sometimes so prolonged that it compromises their health or they give up in frustration. According to the Regulatory Relief Coalition, the process takes between two to 14 days, but for 15 percent of physicians, it can take from 15 to more than 31 days.

Brad C. Klein, MD, MBA, FAAN, who chairs the AAN Medical Economics and Practice Committee, knows all too well how the system consumes resources for neurologic practices. He cites the recent case of a patient for whom he prescribed ubrogepant (Ubrelvy) after failing triptan therapies which were on formulary. After an initial submission online, the insurance company requested additional information and required multiple duplicate resubmissions in both paper and electronic format subsequently. The process, which should have taken 10 minutes to complete, took 3.5 hours over several weeks instead. Sadly, it is being repeated in practices across the country on a daily basis.

The AAN has worked for many years to advance PA reform with Congress and the federal administration. We have engaged in many discussions with key stakeholders to champion the Improving Seniors' Timely Access to Care Act of 2021 (S. 3018/H.R. 3173), which would establish an electronic prior authorization (ePA) program; standardize and streamline the PA process for routinely approved services; reduce the amount of time an insurer is allowed to consider such requests; and ensure that they are reviewed by qualified medical personnel. The bill, advanced by the House Ways and Means Committee on July 27, 2022, and backed by the AAN and its coalition partners, has become one of the most supported bipartisan bills in Congress. It was selected for the priority agenda of two Neurology on the Hill events, and I am happy to report that this bill was passed in the House on September 14, 2022, and now awaits Senate action.

"Members may think that since it only pertains to Medicare Advantage plans, the legislation is not impactful," said Dr. Klein. However, approximately 28.4 million beneficiaries now choose Medicare Advantage plans — 45 percent of the Medicare population — which has doubled over the last decade. Between the passage of this law, which Dr. Klein hopes is imminent, and some successes with state efforts, progress is being made. Dr.

Klein has tried in the past to get Gold Card access endorsed in Pennsylvania, where he practices, to exempt from PA physicians who are compliant and have a very low denial rate. He would like to see that and other initiatives assurance that patients can remain on medications that are working despite formulary changes; commitment by payers that formulary and authorization policy cannot change more than once yearly; increased transparency and a streamlined internet-based user interface to find policies and relevant criteria to obtain approvals in real time; and the removal of gag rules precluding pharmacies from informing patients about cost-saving sites like GoodRx.

Examples like the one Dr. Klein shared help in legislative advocacy. Shannon M. Kilgore, MD, FAAN, who serves on the AAN Board of Directors, said, "The AMA has created the website Fix Prior Authorization to collect patient and physician stories regarding adverse events related to delays in care which helped lead to the passage of the bill in the House." Dr. Kilgore, who is the vice chair of the AAN delegation to the AMA House of Delegates, ensures collaboration between the two organizations along with other AAN members. She said, "Working with the AMA increases our chance of success on desired reform, which may be more difficult for the much smaller field of neurology to do alone."

In the past, efforts to advocate directly with payers on PA failed to lead to substantive changes. It is clear that only legislative actions can ensure lasting change. Derek Brandt, director of Congressional Affairs at the AAN, said, "We were thrilled to have the Improving Seniors' Timely Access to Care Act pass the House unanimously in September, but much more work is needed to get this bill over the finish line." He urges AAN members who want to help get this done before Congress adjourns in December to contact their Senate offices. "We also expect many state bills focused on prior authorization to be considered early next year when local legislatures come back into session," Brandt added. Because local advocacy can have a huge impact on an issue like this, he encourages members who would like to help advocate for change in their regions to connect with their state neurologic and medical societies, which typically coordinate such efforts within their states.

### WHAT YOU CAN DO TO HELP

#### *Contact your Senate offices.*

If you or your patients have stories that demonstrate the hazards of prior authorization, share them by emailing [advocacy@aan.com](mailto:advocacy@aan.com).

Learn more about how BrainPAC helps advocate for this and other issues important to neurology at [BrainPAC.org](http://BrainPAC.org)





## The physician's real problem isn't burnout

Reeta Achari, MD

Reprint article

<https://www.kevinmd.com/2022/11/the-physicians-real-problem-isnt-burnout.html>

Nov. 25, 2022

I read an article recently suggesting that physicians were burned out from hearing about burnout. The proposed solution was to create systemic changes to help alleviate the burden of complexities of care that have polluted health care delivery. The solutions involved adding a team of individuals, including nurse practitioners, physician's assistants, pharmacy assistants, and other physician extenders.

Once again, rather than focus on the physician-patient relationship on which medicine is based, the "experts" continue to react to an unnecessary system that has been built around and profits from every aspect of health care delivery.

Physicians don't need extenders. We need more time with patients and fewer redundant and pointless tasks. The answer is to reduce the complexities that have been consuming the time physicians should spend with patients.

These systemic burdens have been placed on physicians over a mere 40 years. They are not the way it has always been. They can be undone. This is a situation where stepping back and respecting the pillars of the medical profession is the best option. Understanding and bringing forward the essential parts of the practice of medicine — the human parts — and using current technologies to enhance patient care are the solutions.

Bringing physicians and patients together and honoring that relationship is the key to a positive change in American medicine.

These complexities are not only frustrating physicians. They are frustrating patients and are not helping our general state of health. The distractions of complex insurance contracts and payment systems have done great damage and continue to create anxiety and uncertainty in patients, not to mention the financial stressors that contribute to a lack of well-being.

Why do we pay so much for health care yet pay physicians less yearly? Why are the CEOs of insurance companies profiting while putting systems in place to make it harder for patients to get the care, treatment, and medications they need? Why are physicians having to spend more time with electronic medical record systems than with patients, providing statistical data for the

government and insurance companies, or else they suffer the penalty of reduced reimbursements?

Why have government regulations created multi-layer reporting and billing systems that take care and control away from patients and physicians? Why are Medicare patients only allowed a single lifetime physical when they enter the system, limited yearly blood tests and minimal preventative care at the time of their lives when their health becomes more complex, requiring more attention? How on earth can we expect physicians to see a larger volume of more complex patients in less time to break even due to ever-lowering reimbursements?

Imagine a time when a patient was able to call and make an appointment with a doctor without being asked what insurance they had. The appointment was booked, a minimum of information was required, and the patient saw the physician without having to wait a month or more.

The appointment was usually in a small clinic setting. This is as opposed to a costly large-scale professional office building. These have now been proven to be unhealthy in our current pandemic world and lack any privacy for patients (what good are HIPAA privacy regulations when everyone knows what type of doctor you see as they walk down the hallway).

After the visit is completed, the patient could take their prescription to the pharmacy and have it filled for a reasonable cost. If imaging or bloodwork were necessary, many doctors had X-ray machines in their offices or had joined together in a cooperative arrangement to have an imaging center or laboratory where patients could get testing done at a reasonable, transparent price.

In this model, many people could afford regular doctor visits without breaking the bank. The insurance models were indemnity plans with simple deductibles that asked the patient to pay 20 percent, with the insurance covering 80 percent of the cost. By the way, the patient paid at the time of the appointment and was given a superbill to file with their own insurance for reimbursement.

This uncomplicated, user-friendly system worked well for many decades. In the 1980s, the first step at governmental regulation came into being to create a maximum allowed acceptable rate for Medicare charges, and the relative value unit was born. Then came the Medicare HMOs, which controlled a patient's access to care without ever fulfilling the promise of improved health and reduction in costs.

Managed care clinics have been in existence for many years. Some, such as Kaiser Permanente, have done a good job providing complete care for patients with a systematic approach to health care. Conversely, the managed care systems administered by insurance companies, whose main motivation is profit, have made a killing by delaying or



## The physician's real problem isn't burnout (cont.)

denying health care to patients. As physicians, we made the mistake of signing contracts that gave our authority to an opaque, layered bureaucracy that is now at the heart of what is troubling us and needs to be dismantled.

This same corporate practice of medicine lacks respect for the physician-patient relationship, which is now trying to insert other layers of less-trained providers between physicians and their patients.

Yet, corporate analysts claim that this layer of physician extenders will improve patient satisfaction and care and free up time for physicians. This is a fallacy — no patient wants less time with their doctor.

How do we carry forward the best of the tradition of medicine and incorporate the new, modern, and ever-changing aspects of the world?

I have seen medicine practiced well for many years on three continents in various settings. I am the granddaughter of a small-town physician in India and the daughter of two physicians. My mother practiced obstetrics and gynecology in India and England until the early 1970s.

My father is a neurologist who trained and practiced in academics and had independent private practices in India, England and the United States.

The one clear commonality in the delivery of quality care in a satisfying way for patients and physicians is time. You can't make more of it, and distributing a patient's time amongst a variety of lesser-trained individuals does not promote quality. The appearance of time with your physician is not the same as actual time with your physician. Smoke and mirrors don't work in medicine; there is too much at stake.

It's time to step back and take a good look at what is working and what isn't. It's time to bring back the essence of care, the physician-patient relationship, and place it at the pinnacle of any model.

Let's ask which elements of our system support this and promote and enhance those elements. If anything takes time or focus away from the main principle, let's remove or replace it. Whether it's the EMR, payment models, prior authorizations, or even automated phone systems, let's rethink things so the two main people — the patient and the physician — are supported, and excellent care is allowed to be delivered with compassion, care, and time. Only then will we truly heal what ails us.



# Summer Conference 2023

## JULY 21-22

La Cantera, San Antonio



## Ecilizumab therapy in a seronegative patient with NMOSD: A case report

Alejandra Duque-Ramirez, MD<sup>1</sup>. Rebecca S Romero, MD, FAAN<sup>2</sup>.

<sup>1</sup>Third-year resident, Neurology Department, University of Texas Health Science Center at San Antonio, San Antonio, Texas.

<sup>2</sup>Associate Professor of Neurology, Associate Program Director of Neurology, Director of Multiple Sclerosis Clinic, Neurology Department, University of Texas Health Science Center at San Antonio, San Antonio, Texas.

### KEY WORDS

**Seronegative, astrocytes, membrane attack complex, relapse**

### ABSTRACT

We report the case of a 42 years-old female with bilateral optic neuritis. She was later found to have demyelinating lesions in her brainstem, cervical and thoracic spinal cord. NMOSD diagnosis was made despite AQP4 antibodies being negative since the patient met clinical and radiologic criteria for the disease. Attempted therapies included pulsed steroids, Tocilizumab, maintenance plasma exchange therapy, Mycophenolate mofetil, and Rituximab but she continued to have recurrent episodes of optic neuritis. Once Ecilizumab was started, the patient became stable and had a more prolonged remission. Due to insurance authorization issues, Ecilizumab was interrupted, and the patient relapsed again.

The purpose of this case report is to emphasize the appropriate response to therapy seen with this terminal complement inhibitor, even in a seronegative patient. There is a need to include these patients in clinical studies to avoid treatment delays and further accumulation of disability.

### INTRODUCTION

Neuromyelitis Optica spectrum disorder (NMOSD) is a neurologic, immune-mediated disease that affects the central nervous system causing a wide variety of presentations. Signs and symptoms include those corresponding to optic neuritis (ON), myelitis, brainstem syndromes, area postrema syndromes (APS), diencephalic syndromes and/or cerebral syndromes with matching NMOSD-typical structural lesions. This entity was thought to be a variant of Multiple Sclerosis (MS) but since 2004, with the discovery of anti-aquaporin 4 (AQP4) antibodies, the illness has been understood as a separate disease, with different epidemiological targets, pathophysiology, diagnosis criteria, treatment, and prognosis (Lennon et al., 2004).

Around 75% of patients with NMOSD have been found to have anti-AQP4 antibodies; however, there is still a significant percentage of patients that don't have them but still have clinical manifestations of the disease (Huda et al., 2019). These seronegative patients need to fulfill more specific criteria to be diagnosed but are often excluded from new therapeutic studies which poses a challenge for physicians taking care of them.

In this report, we present the case of a 42 years-old female

that presented to our Neurology clinic with symptoms of ON that then progressed to develop acute myelitis and functional deterioration. Her AQP4 antibodies were negative but she met criteria for seronegative NMOSD diagnosis. She failed multiple immunosuppressive therapies and only exhibited disease stabilization while on treatment with Ecilizumab, a terminal complement inhibitor that is FDA approved for the treatment of AQP4 positive NMOSD patients.

Ecilizumab was approved by the FDA in June 2019 for the treatment of seropositive NMOSD patients. It is a monoclonal antibody that works by decreasing astrocyte loss by binding to and inhibiting C5, a terminal complement protein that participates in the pro-inflammatory cascade and membrane attack complex by converting to C5a and C5b (Thomas et al., 1996) (Alexion pharmaceuticals). It has proven to decrease the frequency of relapses in these patients, but further studies are required to establish its impact on the overall quality of life and functionality of this population.

Moreover, during the COVID-19 pandemic, Ecilizumab has demonstrated to be a safe therapy for NMOSD patients as it causes a targeted response against the complement system, without causing generalized immunosuppression.

### CASE REPORT

A 42 years-old woman presented to the University of Texas Health Science Center at San Antonio Neurology clinic in 2015 complaining of worsening bilateral vision. Her visual disturbances first started in 2014 with tunneled vision without pain, she visited a uveitis specialist in that opportunity and was diagnosed with retinal vasculitis. The patient was treated with IV steroids, but no significant improvement was noted. Her Rheumatologist then started her on IV Cyclophosphamide pulses for 5 months which managed to stabilize her vision without restoring it to its baseline. A year later, she came to the Neurology clinic complaining of recurrence of a, now painful, "tunneled vision". She had a past medical history of mixed connective tissue disorder, seronegative rheumatoid arthritis, senile cataracts, migraines, hyperlipidemia, and hypothyroidism. Family history was remarkable for systemic lupus erythematosus (SLE) in her mother and scleroderma and Sjogren's syndrome in a maternal aunt.

Her initial neurological exam revealed distorted colors vision on the left and absence of them on the right. Could only count fingers on central vision bilaterally and had marked bilateral optic nerve atrophy on fundoscopic exam. Also had a subtle



truncal ataxia. Comprehensive blood work-up included normal WBC, ESR, TSH, vitamin B12 level, ACE serum level, lysozyme, C3, and C4 levels. She also had a mildly elevated CRP, and negative AQP4 and MOG antibodies. Tests also revealed negative ANA, RF, cryoglobulin, dsDNA and SSA/SSB antibodies, HIV, syphilis and QuantiFERON gold results. MR Brain and orbits showed stable scattered periventricular T2/FLAIR hyperintense white matter lesions within the right frontal periventricular region, without lesions on optic nerves to suggest ON. MR Cervical and thoracic spine displayed abnormal increased T2 signal involving the ventral upper medulla and anterior spinal cord at C5-C6/C6-C7 and multiple skip areas of hyperintense T2/STIR signal within the thoracic spinal cord.

Additional testing included OCT with bilateral thinning of retina but preserved retinal nerve fiber layers. Fluorescein angiography did not show active leakage at optic nerve, vessels, or macula. Repeat MR orbits revealed bilateral optic nerve hyperintensities suggesting bilateral ON and AQP4 antibodies testing was repeated to be performed by cell-based assay and came back negative again. Differential diagnosis included NMO spectrum disorder, sarcoidosis, SLE and MS among other etiologies. A prednisone taper was prescribed while further testing was completed, the patient also received 5 cycles of plasmapheresis with improvement of visual acuity to 20/40 bilaterally.

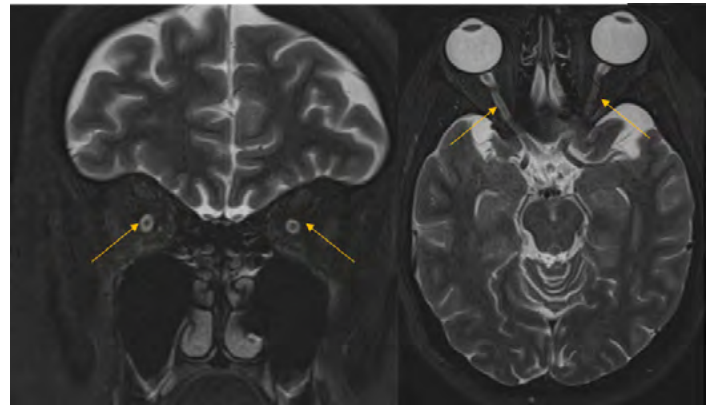
Over the course of the next three years, the patient was trialed on Tocilizumab, maintenance plasma exchange therapy, Mycophenolate mofetil, and Rituximab with continuous bouts of optic neuritis requiring more than 6 admissions to the hospital for acute immunosuppressive therapy. By year 2018, the patient was legally blind with no perception on right eye and only light perception in left eye. She also exhibited progressive neck pain, left arm weakness, and unsteadiness with frequent falls. Repeat cervical spine MR showed longitudinally extensive transverse myelitis (LETM) affecting C3, C4 and C5 segments. Although she remained seronegative, due to the repeated therapeutic failure of multiple agents she was started on Eculizumab therapy in February of 2019 with improved energy, gait and left upper and lower extremities strength after a 6-month trial.

After initial insurance authorization ended, there was a 1-month delay in therapy that led to the patient developing worsening bilateral upper extremities weakness and imbalance. Two new areas of enhancement in brain and cervical spine MRIs were also seen. The patient was eventually able to continue her treatment with Eculizumab and has since tolerated the medication well. She has not had new relapses or required a new admission to the hospital. The only recent new symptoms include declining gastroparesis, shingles at C2 dermatome and progression of alopecia over same area.

This patient with relapsing bilateral ON, one episode of LETM in 2018, imaging showing multiple then-enhancing lesions, and negative cell-assay AQP4/MOG antibodies that was moderately responsive to acute immunotherapy and

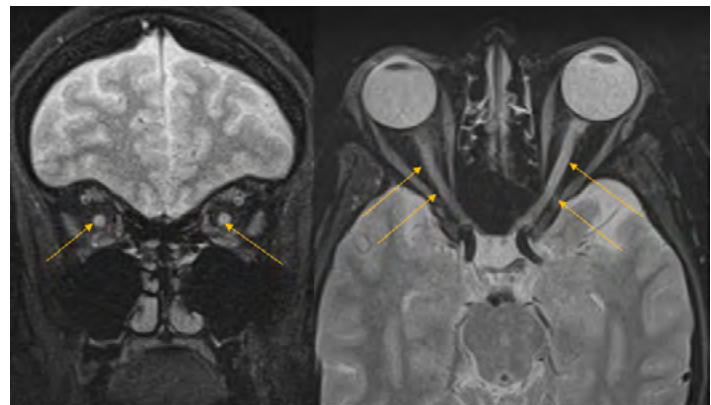
refractory to multiple long-term immunosuppressive therapies met criteria for seronegative NMOSD.

## IMAGES



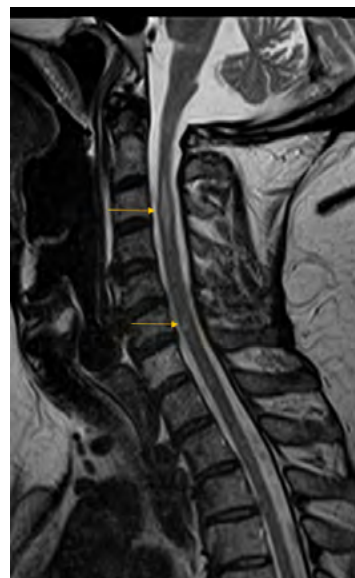**Image 1: Baseline MRIs**

*T2WI with fat saturation showing mildly atrophic bilateral optic nerves without signal abnormality*



**Image 2: ON in orbit MR**

*Coronal/Axial T2WI with fat saturation showing increased bilateral optic nerves signal intensity one year later.*



**Image 3:  
LETM in C-spine MR**

*T2WI showing Longitudinally Extensive Transverse Myelitis in cervical spine*

## DISCUSSION

NMOSD is a CNS immune-mediated disease characterized by inflammation and demyelination affecting the optic nerves and spinal cord in greater extent, also involving the area postrema, diencephalon and brain in lesser degree. Patients tend to progressively accumulate disability as recovery from relapses is not often complete. After 10 years, 60% of patients will be legally blind in one eye (Biousse & Newman, 2016). Relapses occur in 55% of patients after one year and in 78% of patients after three years (Kleiter et al., 2016; Morrow & Wingerchuk, 2012). This disease usually affects more women than men and is also more prevalent in non-Caucasian populations (Oh & Levy, 2012; Weinshenker & Wingerchuk, 2017), with Asians and people with African ancestry being at greater risk (Mealy et al., 2018; Pittock & Lucchinetti, 2016).

In the past, NMOSD was thought to be a variant of MS. However, with the discovery of anti-AQP4 antibodies, observation of disease behavior, poor recovery after relapse and unfavorable response to MS therapies; it was understood that they are different entities that warrant distinct approaches and therapeutic targets.

AQP4 are water channels that are expressed broadly in the CNS, but mostly within the astrocytes end-feet (Lennon et al., 2004, 2005). Their distribution within the CNS highly correlates with NMOSD anatomical lesions (Misu et al., 2005). In NMOSD, antibodies bind to the extracellular domain of the AQP4 receptors and trigger cell- and complement – mediated cascades of cellular damage. Specifically, with astrocytes playing a big role on the blood-brain barrier; their destruction facilitates the permeation of pro-inflammatory substances that end-up causing oligodendrocyte impairment and demyelination (Hinson et al., 2007, 2008). Different from MS, the secondary oligodendrocyte damage seen in NMOSD mostly comes from the astrocytes inability to protect and support their surrounding cells (Misu et al., 2007; Ratelade et al., 2012).

Cell-based assay is the most sensitive and specific method to detect AQP4 antibodies. Enzyme-linked immunosorbent assay (ELISA) is also widely used but not as specific (Waters et al., 2016). If meeting the most recent seronegative NMOSD criteria, patients should be treated as such without waiting for further antibody confirmation. Serostatus, however, can change throughout the course of the disease and repeat testing can be done without delaying treatment. In this case, even though the patient was AQP4 negative, she exhibited two core clinical characteristics (ON and LETM) during different clinical attacks. Episodes were also confirmed on MRI which made it possible to diagnose her with NMOSD (Wingerchuk et al., 2015).

It has also been proposed that seronegative patients might have low titers of anti AQP1 antibodies. They target another astrocyte water channel and could mediate disease pathogenesis similar to antibodies against AQP4 (Bernard-Valnet et al., 2015; Tzartos et al., 2013). Anti AQP1 testing is not widely available yet. There are other epidemiological differences noted in the seronegative population. For instance, studies have shown that the predominance of female patients is not as robust in these

antibody negative cases. They also tend to present at a younger age and affect more Caucasians (Badri et al., 2016; Fujihara, 2019; Marignier et al., 2013)

Eculizumab (Soliris) is the first agent to be specifically approved for the treatment of seropositive NMOSD. During the clinical trials for NMOSD, only seropositive patients were included in the studies. It was proven that the medication reduced the overall relapse rate, even on the patients that were not on therapy with other immunosuppressive agents (Pittock et al., 2019). By inhibiting the terminal complement protein C5, this recombinant humanized monoclonal antibody limits the complement-mediated cascade that ends-up targeting astrocytes for destruction (Rother et al., 2007). If patients with seronegative NMOSD are also thought to have a secondary oligodendrocyte and myelin damage after the disruption of astrocytes, any therapy aiming to prevent astrocyte dysfunction should virtually work on this spectrum of the disease as evidenced by the patient whose case we report.

Therapy with Eculizumab was generally well tolerated based on the PREVENT study report. The most common side effects were upper respiratory tract infections, headaches, nasopharyngitis, nausea and diarrhea. The most dangerous concern arising from treatment with Eculizumab is the increased susceptibility to infections from encapsulated bacteria as the complement system is impaired in these patients (Pittock et al., 2019), for which they should be vaccinated against meningococcus prior to initiation of therapy. Our patient did not exhibit any of these symptoms or diseases, but experienced worsening alopecia, shingles, and gastroparesis. Further studies are needed to clarify the existence of other therapy-related adverse events or seronegative status-specific side effects.

It is also important to note that during the ongoing Covid-19 pandemic, Eculizumab has been used in clinical trials to treat patients with this viral infection. By limiting the complement activation cascade, this monoclonal antibody prevents the formation of a pro-inflammatory response in the body and creates a more targeted immunosuppression, also making the patient less vulnerable to other pathogens (Annane et al., 2020)

Although N- Momentum trial for Inebilizumab and SAKuraStar for Satralizumab did include seronegative patients in their studies, they were not sufficiently powered to determine the existence of true statistical differences in therapy response. This supports the need for bigger and adequately sampled studies in the seronegative NMOSD population as having enough evidence could facilitate an FDA approval for therapy and avoid insurance denials and delays in treatment (Tugizova et al., 2021).

## DISCLOSURES

Alejandra Duque Ramirez, MD: Declares that she has no relevant or material financial interests that relate to the work described in this paper.

Rebecca S Romero, MD: Declares that she has done consulting for the following companies: Horizon, EMD Serono, and TG Therapeutics.



## REFERENCES

- Annane, D., Heming, N., Grimaldi-Bensouda, L., Frémeaux-Bacchi, V., Vigan, M., Roux, A.-L., Marchal, A., Michelon, H., Rottman, M., & Moine, P. (2020). Eculizumab as an emergency treatment for adult patients with severe COVID-19 in the intensive care unit: A proof-of-concept study. *EclinicalMedicine*, 28, 100590. <https://doi.org/10.1016/j.eclinm.2020.100590>
- Badri, N., Teleb, M., Syed, S., Wardi, M., Porres-Aguilar, M., & Cruz-Flores, S. (2016). Seronegative Neuromyelitis Optica: A Case Report of a Hispanic Male. *Case Reports in Neurology*, 8(2), 102–107. <https://doi.org/10.1159/000446105>
- Bernard-Valnet, R., Liblau, R. S., Vukusic, S., & Marignier, R. (2015). Neuromyelitis optica: a positive appraisal of seronegative cases. *European Journal of Neurology*, 22(12), 1511–e83. <https://doi.org/10.1111/ene.12679>
- Biousse, V., & Newman, N. J. (2016). Diagnosis and clinical features of common optic neuropathies. *The Lancet Neurology*, 15(13), 1355–1367. [https://doi.org/10.1016/S1474-4422\(16\)30237-X](https://doi.org/10.1016/S1474-4422(16)30237-X)
- Fujihara, K. (2019). Neuromyelitis optica spectrum disorders: still evolving and broadening. *Current Opinion in Neurology*, 32(3), 385–394. <https://doi.org/10.1097/WCO.0000000000000694>
- Hinson, S. R., Pittock, S. J., Lucchinetti, C. F., Roemer, S. F., Fryer, J. P., Kryzer, T. J., & Lennon, V. A. (2007). Pathogenic potential of IgG binding to water channel extracellular domain in neuromyelitis optica. *Neurology*, 69(24), 2221–2231. <https://doi.org/10.1212/01.WNL.0000289761.64862.ce>
- Hinson, S. R., Roemer, S. F., Lucchinetti, C. F., Fryer, J. P., Kryzer, T. J., Chamberlain, J. L., Howe, C. L., Pittock, S. J., & Lennon, V. A. (2008). Aquaporin-4-binding autoantibodies in patients with neuromyelitis optica impair glutamate transport by down-regulating EAAT2. *Journal of Experimental Medicine*, 205(11), 2473–2481. <https://doi.org/10.1084/jem.20081241>
- Huda, S., Whittam, D., Bhojak, M., Chamberlain, J., Noonan, C., Jacob, A., & Kneen, R. (2019). Neuromyelitis optica spectrum disorders. *Clinical Medicine*, 19(2), 169–176. <https://doi.org/10.7861/clinmedicine.19-2-169>
- Kleiter, I., Gahlen, A., Borisow, N., Fischer, K., Wernecke, K.-D., Wegner, B., Hellwig, K., Pache, F., Ruprecht, K., Havla, J., Krumbholz, M., Kümpfel, T., Aktas, O., Hartung, H.-P., Ringelstein, M., Geis, C., Kleinschnitz, C., Berthele, A., Hemmer, B., ... Trebst, C. (2016). Neuromyelitis optica: Evaluation of 871 attacks and 1,153 treatment courses. *Annals of Neurology*, 79(2), 206–216. <https://doi.org/10.1002/ana.24554>
- Lennon, V. A., Kryzer, T. J., Pittock, S. J., Verkman, A. S., & Hinson, S. R. (2005). IgG marker of optic-spinal multiple sclerosis binds to the aquaporin-4 water channel. *Journal of Experimental Medicine*, 202(4), 473–477. <https://doi.org/10.1084/jem.20050304>
- Lennon, V. A., Wingerchuk, D. M., Kryzer, T. J., Pittock, S. J., Lucchinetti, C. F., Fujihara, K., Nakashima, I., & Weinshenker, B. G. (2004). A serum autoantibody marker of neuromyelitis optica: distinction from multiple sclerosis. *The Lancet*, 364(9451), 2106–2112. [https://doi.org/10.1016/S0140-6736\(04\)17551-X](https://doi.org/10.1016/S0140-6736(04)17551-X)
- Marignier, R., Bernard-Valnet, R., Giraudon, P., Collongues, N., Papeix, C., Zephir, H., Cavillon, G., Rogemond, V., Casey, R., Frangoulis, B., de Seze, J., Vukusic, S., Honnorat, J., & Confavreux, C. (2013). Aquaporin-4 antibody-negative neuromyelitis optica: Distinct assay sensitivity-dependent entity. *Neurology*, 80(24), 2194–2200. <https://doi.org/10.1212/WNL.0b013e318296e917>
- Mealy, M. A., Kessler, R. A., Rimler, Z., Reid, A., Totonis, L., Cutter, G., Kister, I., & Levy, M. (2018). Mortality in neuromyelitis optica is strongly associated with African ancestry. *Neurology - Neuroimmunology Neuroinflammation*, 5(4), e468. <https://doi.org/10.1212/NXI.0000000000000468>
- Misu, T., Fujihara, K., Kakita, A., Konno, H., Nakamura, M., Watanabe, S., Takahashi, T., Nakashima, I., Takahashi, H., & Itoyama, Y. (2007). Loss of aquaporin 4 in lesions of neuromyelitis optica: distinction from multiple sclerosis. *Brain*, 130(5), 1224–1234. <https://doi.org/10.1093/brain/awm047>
- Misu, T., Fujihara, K., Nakashima, I., Sato, S., & Itoyama, Y. (2005). Intractable hiccup and nausea with periaqueductal lesions in neuromyelitis optica. *Neurology*, 65(9), 1479–1482. <https://doi.org/10.1212/01.wnl.0000183151.19351.82>
- Morrow, M. J., & Wingerchuk, D. (2012). Neuromyelitis Optica. *Journal of Neuro-Ophthalmology*, 32(2), 154–166. <https://doi.org/10.1097/WNO.0b013e31825662f1>
- Oh, J., & Levy, M. (2012). Neuromyelitis Optica: An Antibody-Mediated Disorder of the Central Nervous System. *Neurology Research International*, 2012, 1–13. <https://doi.org/10.1155/2012/460825>
- Pittock, S. J., Berthele, A., Fujihara, K., Kim, H. J., Levy, M., Palace, J., Nakashima, I., Terzi, M., Totolyan, N., Viswanathan, S., Wang, K.-C., Pace, A., Fujita, K. P., Armstrong, R., & Wingerchuk, D. M. (2019). Eculizumab in Aquaporin-4-Positive Neuromyelitis Optica Spectrum Disorder. *New England Journal of Medicine*, 381(7), 614–625. <https://doi.org/10.1056/NEJMoa1900866>
- Pittock, S. J., & Lucchinetti, C. F. (2016). Neuromyelitis optica and the evolving spectrum of autoimmune aquaporin-4 channelopathies: a decade later. *Annals of the New York Academy of Sciences*, 1366(1), 20–39. <https://doi.org/10.1111/nyas.12794>
- Ratelade, J., Zhang, H., Saadoun, S., Bennett, J. L., Papadopoulos, M. C., & Verkman, A. S. (2012). Neuromyelitis optica IgG and natural killer cells produce NMO lesions in mice without myelin loss. *Acta Neuropathologica*, 123(6), 861–872. <https://doi.org/10.1007/s00401-012-0986-4>
- Rother, R. P., Rollins, S. A., Mojcik, C. F., Brodsky, R. A., & Bell, L. (2007). Discovery and development of the complement inhibitor eculizumab for the treatment of paroxysmal nocturnal hemoglobinuria. *Nature Biotechnology*, 25(11), 1256–1264. <https://doi.org/10.1038/nbt1344>
- Thomas, T. C., Rollins, S. A., Rother, R. P., Giannoni, M. A., Hartman, S. L., Elliott, E. A., Nye, S. H., Matis, L. A., Squinto, S. P., & Evans, M. J. (1996). Inhibition of complement activity by humanized anti-C5 antibody and single-chain Fv. *Molecular Immunology*, 33(17–18), 1389–1401. [https://doi.org/10.1016/S0161-5890\(96\)00078-8](https://doi.org/10.1016/S0161-5890(96)00078-8)
- Tugizova, M., Vlahovic, L., Tomczak, A., Wetzel, N. S., & Han, M. H. (2021). New Therapeutic Landscape in Neuromyelitis Optica. *Current Treatment Options in Neurology*, 23(4), 13. <https://doi.org/10.1007/s11940-021-00667-3>
- Tzartos, J. S., Stergiou, C., Kilidireas, K., Zisimopoulou, P., Thomaidis, T., & Tzartos, S. J. (2013). Anti-Aquaporin-1 Autoantibodies in Patients with Neuromyelitis Optica Spectrum Disorders. *PLoS ONE*, 8(9), e74773. <https://doi.org/10.1371/journal.pone.0074773>
- Waters, P., Reindl, M., Saiz, A., Schanda, K., Tuller, F., Kral, V., Nytrova, P., Sobek, O., Nielsen, H. H., Barington, T., Lillevang, S. T., Illes, Z., Rentzsch, K., Berthele, A., Berki, T., Granieri, L., Bertolotto, A., Giometto, B., Zuliani, L., ... Marignier, R. (2016). Multicentre comparison of a diagnostic assay: aquaporin-4 antibodies in neuromyelitis optica. *Journal of Neurology, Neurosurgery & Psychiatry*, 87(9), 1005–1015. <https://doi.org/10.1136/jnnp-2015-312601>
- Weinshenker, B. G., & Wingerchuk, D. M. (2017). Neuromyelitis Spectrum Disorders. *Mayo Clinic Proceedings*, 92(4), 663–679. <https://doi.org/10.1016/j.mayocp.2016.12.014>
- Wingerchuk, D. M., Banwell, B., Bennett, J. L., Cabre, P., Carroll, W., Chitnis, T., de Seze, J., Fujihara, K., Greenberg, B., Jacob, A., Jarius, S., Lana-Peixoto, M., Levy, M., Simon, J. H., Tenenbaum, S., Traboulsee, A. L., Waters, P., Wellik, K. E., & Weinshenker, B. G. (2015). International consensus diagnostic criteria for neuromyelitis optica spectrum disorders. *Neurology*, 85(2), 177–189. <https://doi.org/10.1212/WNL.0000000000001729>



# Business of Medicine

## PROGRAM FOR RESIDENTS

A “behind the scenes” look at running a practice

**WHO?** *Neurology residents in their third or fourth year of study.*


**WHAT?** *Learning about:*

- Medicare and Medicaid plans
- Laws and benefits
- Coding rules
- Billing and payment processes for patients
- Physician payment plans

**WHERE?** *Rotation sites in Austin, Dallas, San Antonio and Houston*

For more information and to apply, visit the [TNS Website.](#)





## Epileptic Hemiprosopometamorphopsic Hallucinosi

*KJ Oommen, MD<sup>1</sup> and Jonathan Kopel, PhD<sup>2</sup>*

1. Founding Director, Jay & Virginia Crofoot Epilepsy Monitoring Unit, Covenant Hospital, and Director, Epilepsy Clinics, Covenant Medical Group, Lubbock, TX 79410.

2. Jonathan Kopel, MD PhD Student, MSIV, TTUHSC, Lubbock, TX, 79430)

### ABSTRACT

A visual hallucination is the perception of an image without an external stimulus through the eyes. Complex or formed hallucinations include images of people, faces, animals and objects and require retrieval of highly processed visual images from visual association cortices, either from irritative lesions in the brain, electrical excitation from delirious or toxic states and hallucinogenic drugs. Disorders that cause deficits in higher-level visual processing include visual object agnosia, topographagnosia, prosopagnosia, and several others. In the current case, the patient had a unique visual hallucination in which the right half of the faces he saw, but could not recognize (prosopagnosia), were distorted (as if they were melting). This type of hallucination is very rare and unique and may provide insights into the phenomenon of visual processing and into the location where such processing occurs from their causative lesions, when associated with brain lesions. We propose that this phenomenon which has not been described before in patients with epilepsy, may be called “hemiprosopometamorphopsic hallucinosi”. The case and its clinical features support the results of in-vivo electrical stimulation experiments that showed the association between the fusiform gyrus on the right side and metamorphopsia for the first time. There were no case reports of a similar phenomenon that we were able to find in the literature, but a few cases of visual illusions were found that bear some similarities to the present case from lesions within non-identical locations in the brain.

### CASE REPORT

At the time of his initial presentation to our epilepsy specialty clinic, the patient was a 67-year-old man with a history of having had a single convulsive seizure at age 54. His past medical history was significant for occasionally seeing floaters which he likened to “an ameba moving from the lower left to his upper right visual field, from his childhood. This experience was sporadic, not associated with alteration of awareness and remained undiagnosed until he was 54, when he suffered a convulsive seizure at work. Before the seizure, he began seeing a red and white ball in his visual field in its center, which then became so bright that he felt like it “illuminated the whole room”. He has no memory of what happened for about 10 minutes, until after he woke up. He then remembers being on a gurney being pushed by paramedics. The customer he was serving prior to the event later told him that he had a strange look on his face before

he fell off his chair and went into convulsions. He did not suffer any injury from the fall, bite his tongue nor was he incontinent.

He was taken to the local ER where he was evaluated and was released. Later, he was seen by a neurologist who placed him on Topamax (topiramate) which was discontinued after 40 days followed by Depakote 250 mg per day which he had taken ever since. After the generalized tonic-clonic seizure, the floaters (the moving objects in his visual field since childhood) changed to what he referred to as bursts of fireworks, random colors and faces familiar to him from his childhood onwards, which he could not recognize because the faces appeared to him to be “melting” on the right. These visual symptoms recurred sporadically since the convulsive seizure at age 54 mentioned above, for short periods of time at a rate of about once a year with spontaneous remissions, the longest duration of symptoms being 4 days. He experienced one such episode after he turned 67 and later in the same year, he was referred to our clinic following another episode of 5 days of an intermittent nonspecific headache without nausea, vomiting or intolerance to light or sound, but with certain visual symptoms summarized below, resolving on the 6th day. He kept a diary of those symptoms during that period, and they were:

Day 1. Floaters, lower left to upper right, shapes, caricatures, color.

Day 2. Floaters (shapes, caricatures) continue with headache above right eye.

Day 3. Floaters are faces – recognizable but not identifiable by name; many, I have known for 50 years or so, as from high school or TV, with their faces, right eye in particular, distorted. Headache subsided.

Day 4. The parade of faces continues, and the headache is back, more severe. Not sure if it is weather related from the rain yesterday or the cold weather today.

Day 5. Floaters are gone, but printed materials in newspapers and the TV bottom crawlers appear as though, they were made with varied fonts. “UnneRving to say the least”. Facial distortions until about noon.

Day 6. Floater and headache free today. Facial distortion remains. The right eye (of the faces) appears to be looking up and crossed.

His medical history was significant for gout, obesity and hyperlipidemia. On general physical, he was moderately

obese. Neurological examination was normal. His initial CT of the head following his seizure at 54 in July 2005 was reported to be normal. The MRI showed a small focus of increased FLAIR signal in the occipital lobe. Three months later, in October, the MRI of the brain showed a focus of FLAIR hyperintensity in the right occipital lobe (Images 1 and 2) with increased signal on diffusion-weighted image. A small vascular malformation was noted in the right cerebellar hemisphere (See arrow in Image 3). An MRV was ordered because of the latter finding and it showed small venous angioma (See arrow in Image 4) in the right occipitotemporal region. The initial EEG on presentation in July and a follow up video EEG study in October were normal.

## DEFINITION AND CLASSIFICATION OF VISUAL HALLUCINATIONS

A visual hallucination is the perception of an image without an external stimulus through the eyes. When a visual signal is perceived differently from the real object, it is called an illusion and includes, macropsia wherein the object is seen larger; micropsia, wherein it is seen smaller and metamorphopsia in which it is oddly shaped or malformed as in the case of "Alice in Wonderland Syndrome".

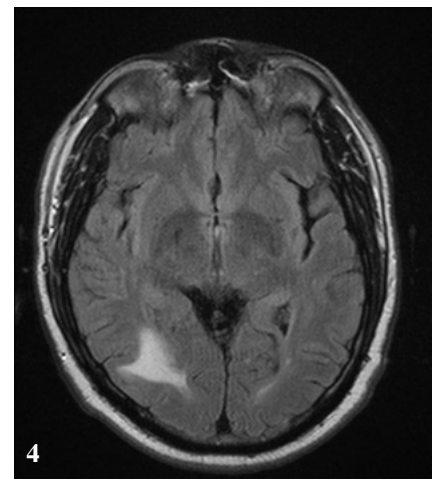
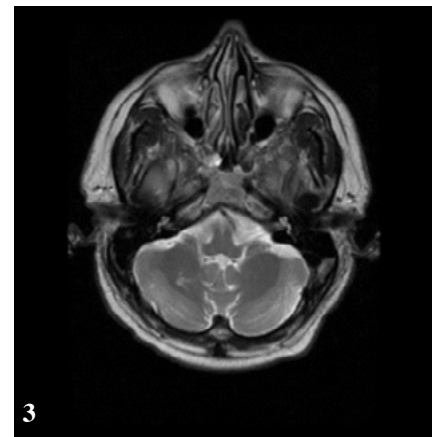
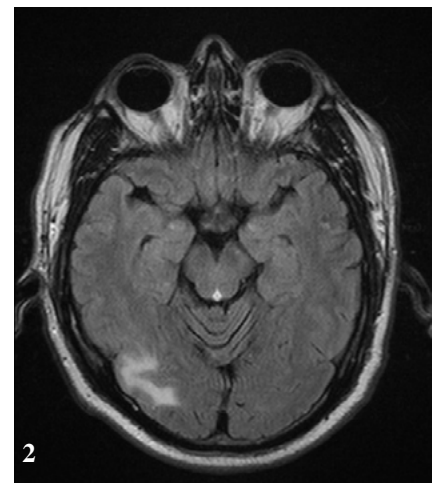
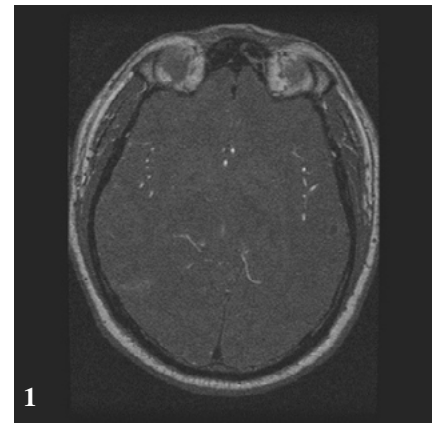
A useful scheme of classifying hallucinations is into (a) simple and (b) complex types. Simple or unformed hallucinations consist of elementary forms such as bright lights (phosphenes), dark spots (Scotomas), geometric figures, zig-zag lines (fortification spectra) etc., and can result from injury to the visual pathways anywhere from the retina to the primary visual cortex. These are most commonly seen in patients with migraine headaches and in patients with epilepsy without evidence of injury and are believed to be due to cerebral blood flow changes in migraine and due to aberrant electrical activity in the case of epilepsy. Complex or formed hallucinations include images of people, faces, animals and objects and require retrieval of highly processed visual images from visual association cortices, either from irritative lesions in the brain, electrical excitation from delirious or toxic states and hallucinogenic drugs. Disorders that cause deficits in higher-level visual processing include visual object agnosia, topographagnosia, prosopagnosia, alexia, achromatopsia, akinetopsia, Balint syndrome, and astereopsis.

In the current case, the patient had a unique visual hallucination in which the right half of the faces he saw, but could not recognize (prosopagnosia), were distorted (as if they were melting). This type of hallucination is very rare and unique and may provide insights into the phenomenon of visual processing and into the location where such processing occurs from their causative lesions, when associated with brain lesions. We propose that this phenomenon which has not been described before in patients with epilepsy, may be called "hemiprosopometamorphopsic hallucinosis".

## REVIEW OF LITERATURE

There were no case reports of a similar phenomenon that we were able to find in the literature, but a few cases of visual illusions were found that bear some similarities to the present case from lesions in non-identical locations in the brain. One such case we found in the literature was that of a patient with a left putaminal hemorrhage, who saw the right half of his doctor's body during rounds in a distorted way (1), three days after the patient suffered the stroke. That however was a perceptual distortion of the entire hemibody or an illusion, from involvement of his left visual pathway and not a hemifacial hallucination.

Another case of prosopometamorphopsia (of the full face) was reported in the *Lancet* (2) by 3 psychologists from the Netherlands. The patient's psychiatrist who initially treated the lady, prescribed citalopram and quetiapine and because of lack of response the physician emailed the case to Dr. Oliver Sacks, who referred the patient to a neuropsychology team in the Netherlands which published the case and





is quoted here in part: "In July, 2011, a 52-year-old woman presented to our psychiatric outpatient clinic in The Hague with a life-long history of seeing people's faces change into dragon-like faces and hallucinating similar faces many times a day. She could perceive and recognise ("recognize" in American spelling) actual faces, but after several minutes they turned black, grew long, pointy ears and a protruding snout, and displayed a reptiloid skin and huge eyes in bright yellow, green, blue, or red. She saw similar dragon-like faces drifting towards her many times a day from the walls, electrical sockets, or the computer screen, in both the presence and absence of face-like patterns, and at night she saw many dragon-like faces in the dark." The MRI showed multiple white matter lesions and the patient responded to valproic acid, but it was changed as she began hearing loud banging noises, to rivastigmine, "which reduced the frequency of auditory symptoms and kept visual symptoms sufficiently under control for her to function normally".

A third case was that of a patient (3) with a right temporal lesion who perceived the right lower half of the face of the person in front of him to appear swollen (an illusion) without visual hallucinations, prosopagnosia or deficits of body awareness.

It is important to note that in many case reports including Bodamer's (4) original report of prosopagnosia in 1947, and since, the patients did have other elements of agnosias. Therefore, pure cases of hemifacial distortion resulting in prosopagnosia like the current case which are extremely rare, may be helpful in understanding the localization and the mechanisms of facial recognition. Such is the state of our current capabilities in localization of brain function and that is what prompted the saying "Neurology owes more to its diseases than its diseases owe to neurology". It is encouraging that new technologies, not available in the past, using MRI such as

blood oxygen level dependent (BOLD) imaging and direct cortical stimulation are beginning to shed more light on the mechanisms of visual processing.

## DISCUSSION

Visual processing is a task that the brain seems to tackle effortlessly. It is hierarchical, highly complex and occurs at multiple levels all the way from the retina up to the higher cortical centers. Low level processing involves recognition of shapes, shades and colors and high-level processing involves object recognition, discrimination, the assignment of various attributes to perceived images in collaboration with other senses, memory registration and retrieval and tagging it to other memory functions for cross referencing. Further, the brain adjusts the images for our motion in space probably in collaboration with the saccadic and slow pursuit centers in the frontal and parietal cortices, so that the images we perceive do not blur with our movement like the cameras of old caused the picture to get blurred with movement of

the object and or the camera. And that is just the beginning of brain's capabilities, let alone an eagle's ability to spot, lock the target in its visual field, dive and then land precisely on its prey and our ability to calculate the speed of moving objects, aim, shoot and hit moving or oscillating targets and the myriad other ways the brain can process images.

Legend has it that Arjuna, the greatest archer of all time, referred to in the Indian epic Mahabharatha, could hit a bird on a tree with his arrow, by simply looking at the bird's reflection in a pond. You may also have seen current day feats of knife throwers performing their thrilling art of precisely hitting a spinning board sparing an accomplice who is "eagle spread" on the same board demonstrating the brain's ability for visual processing and to coordinate it with precise hand movements. In this article we will only deal with the aspects of processing for us to understand our patient's perceptual distortion of his visual hallucinations and its anatomical basis.

The image formed on the retina by the crystalline lens is upside down and oriented "left side right". Eventually, the brain makes it upright but does not laterally invert it as it happens to the image in a plane mirror, wherein we see ourselves in the mirror with our left and right sides of the body image to our left and right respectively in a reverse orientation, unlike one would see a person facing us, in which case his or her right will be to our left and the left will be to our right.

Physicists have long known this phenomenon and referred to it as "lateral inversion" regarding it a "property" of plain mirrors as opposed to convex lenses that laterally and vertically invert the images produced at their focal points as light passes through them. This is truly quintessential because the brain "must" invert the retinal image both vertically and laterally, so that upright objects we see remain upright and not inverted and we see all objects, the landscape, the buildings in the panorama and people in their true orientation, with their left side on our right and the right side on our left. Imagine the confusion in perception it will cause otherwise!

The light energy that enters the eye through the cornea passes through the pupil and then the crystalline lens, which focuses it upon the retina. The light-sensing rods and cones respond to different levels of light and act as transducers for night vision and color vision respectively. These photoreceptor cells convey the energy they produce proportional to the incident light, to the bipolar cells that excite the retinal ganglion cells. The centripetal (afferent) axons of these cells form a bundle at the optic disc and form the optic nerve from each eye. The temporal and nasal components of these fibers from each eye behave differently in that the temporal components, continue ipsilaterally whereas the nasal components decussate in the optic chiasm in such a way that the upper and lower retinal fibers remain in an antero-posterior orientation prior to forming the optic tracts. This process allows the left retinal halves of each eye which perceive the right half of each visual field to be carried to the

left occipital lobe and the right retinal halves of both eyes perceive the left visual field to be carried to the right occipital lobe. From there the signals are passed on for higher level processing and sundry other functions that we will not delve into in this article and limit our discussion to the phenomenon at hand, because anything else is beyond the scope of our goal of understanding the distortion of facial images that led to the patient's agnosia of the faces that he perceived in his hallucinations.

The fact that brain is capable of vertically and not laterally inverting perceived images in a functionally reversible fashion has been known since the classic experiments by Dr. George Malcolm Stratton, (September 26, 1865 – October 8, 1957), an American psychologist, who founded the department of psychology and started the first experimental psychology laboratory in the USA, at the University of California, Berkeley. Stratton pioneered the study of perception in vision by wearing special glasses (4) which inverted images up and down and left and right. He demonstrated the “logical” vertical inversion of images by brain for the purpose of visual perspective accuracy through his experiments using a complex lens system that inverted the images before they fell on the retina and its functional reversal, once the lens system is removed. Where such processing takes place has been studied for a long time since, and will not be discussed in this article.

Impairment of the visual processing required for facial recognition results in prosopagnosia, a term first used by Bodamer in 1947 (4). Its anatomical basis is still unclear, although its occurrence in frontotemporal dementias with posterior temporal atrophy supports a temporal location. However, that localization is made nebulous by the presence of additional agnostic phenomena in posterior temporal dementias. Other case reports of neurological lesions of various pathologies and locations (6-12) also lack purity of symptomatology (an isolated visual cognitive deficit) due to presence of other visual cognitive deficits. That is where cases such as that of our patient become relevant in pinpointing the location of the processing of individual visual gnostic functions. To understand this, let us look at two of the best studied areas for object and facial recognition, namely the parahippocampal gyrus and the fusiform gyrus.

Facial recognition which occurs at close quarters and recognition of structures and buildings which typically occurs from a distance have been shown to have two distinct loci in the brain. Models of visual processing based on stimulus responsiveness paradigms have distinguished the parahippocampal place area (PPA) located in the parahippocampal region of the posterior temporal lobe to show heightened activation when presented with scenes of buildings and places (13), whereas the fusiform face area (FFA) adjacent to it responds mostly strongly to faces and face-like stimuli (14). The PPA is involved in both spatial memory and spatial navigation (15). Patients who have experienced damage to the PPA demonstrate

topographic disorientation and become unable to navigate familiar and unfamiliar surroundings (16). However, just like the PPA, the FFA also shows activation for other stimuli and can be trained to specialize in the visual processing of objects by experts. Studies of bird watchers or car experts who have adapted a visual skill in identifying traits of birds and cars have activation of the FFA when those stimuli were presented, because these experts have developed FFA activation for their respective specific visual expertise.

Cortical Stimulation experiments of the right lateral fusiform gyrus (FG) has been shown to induce prosopometamorphopsia and offers a causal link between face perception and FG (17) and it appears to be right dominant, because stimulation of the contralateral (homologous) cortical region resulted only in perception of phosphenes (18), suggesting a right hemispheric dominance for face recognition, and supports studies of patients with face recognition impairment following brain damage which also point to the ventral occipito-temporal (VOT) cortex (19), with a right hemispheric dominance.

Our patient's initial CT of head was negative excluding a demonstrable primary hemorrhagic event but the later appearance of subcortical FLAIR signal seen in Images 1 and 2, is consistent with an old subcortical stroke and suggests the prior occurrence of either a slow leak (petechial hemorrhage) which in all probability caused his first and only convulsive seizure, missed on the original CT, but suggested by the MRI done three months later. From this, one has to surmise that the initial event of a possible leak later became larger or induced vasospasm in a local small vessel, resulting in the encephalomalacia noted in the MRI (Images 1 and 2) taken 3 months later. An MR angiogram was performed following this because of the presence of a venous angioma in the right cerebellar hemisphere (arrow in Image 3). The study showed the presence of an enlarged vein (arrow in Image 4) in the area of the encephalomalacia noted in Images 1 and 2, suggesting that venous angiomas often considered benign may cause focal seizures (such as the visual hallucinations the patient suffered from childhood in this case) possibly from irritation caused by sporadic leakage of blood or due to the presence of associated migrational abnormalities in the area and that such lesions may cause encephalomalacia from larger leakages of blood around it, albeit rarely.

Prosopagnosias are often due to hemifacial distortions among other factors. The location of the encephalomalacia in the occipitotemporal region in this patient, confirms the long-suspected association between the fusiform gyrus and facial recognition. One point to note regarding this conclusion is that it does assume that the epileptogenic zone and the symptomatic zone in this patient were not the same, but were close enough to cause interference with hemifacial image fusion by electrical excitation of the area, but not to cause other visual impairments such as visual field defects or other gnostic disturbances.



## CONCLUSION

The primary visual cortex receives information from only one half of any object in our visual field and the two halves have to fuse somewhere before it is transmitted for cognition to occur for which it is generally accepted that the information has to be relayed to the Wernicke's area, which then will have to find a "match" for the fused image (face in this case) in an area wherever such information is stored for later retrieval. Under such a sequence, the posterior occipitotemporal region or the FFA specifically only acts as a location where the fusion of the images occur and not the process of recognition itself, which is a function of the Wernicke's area. Our patient was able to see and recognize faces of people during his symptomatic period, which means that the functions of the primary visual cortex of perception, secondary process of fusion of images and the tertiary process of recognition were intact, until the electrical disturbance (due to the seizure caused by the electrical disturbance in the region of the venous angioma) interfered with the fusion of the false image perceived during the hallucinatory experience. This means that the lesion in our patient was close to the area where the fusion occurs (FG) and that it did not destroy it, and that it was close enough to disturb the process of image fusion, interfering with the next step of relaying a fused image to the Wernicke's area for facial recognition. Again, the process of facial recognition itself, which happens once the image arrives the Wernicke's area is beyond the scope of this article. In other words, our patient is a living example of spontaneous, sporadic cortical stimulation as it was demonstrated in vivo in a patient through experimental stimulation of the cortex, performed by Parvizi (17), Rangarajan (18) and others. Perhaps other cases in the future and further experimentation may shed more light on this complex phenomenon.

## REFERENCES

Metamorphopsia and visual hallucinations restricted to the right visual hemifield after a left putaminal haemorrhage, *J Neurol Neurosurg Psychiatry*. 1996 Oct;61(4):420-1. Letters to the Editor. K Shiga, M Makino, Y Ueda, K Nakajima, Department of Neurology, Kyoto Prefectural University of Medicine, Kyoto, Japan

"Prosopometamorphopsia and Facial Halucinations", Dr. Jan Dirk Blom, PhD, Iris EC Sommer, PhD, San Kooops, MSc and Oliver W Sacks, MD, *The Lancet*. Nov 29, 2014, Vol 384. Number 9958 p1901-1998 e58-e61 [https://www.thelancet.com/journals/lancet/issue/vol384no9958/PIIS0140-6736\(14\)X6116-7](https://www.thelancet.com/journals/lancet/issue/vol384no9958/PIIS0140-6736(14)X6116-7)

["Metamorphopsia restricted to the right side of the face associated with a right temporal lobe lesion". H. Miwa, T. Kondo, \*J Neurol\* 254, 1765-1767 \(2007\)](#)

"Bodamer's (1947) paper on prosopagnosia", Hadyn D. Ellis & Melanie Florence (1990), *Cognitive Neuropsychology*, 7:2, 81-105, DOI: 10.1080/02643299008253437

"Vision Without Inversion of the Retinal Image" (PDF). *Psychological Review*. 4 (4): 341-360. doi:10.1037/h0075482.

"Parasagittal parieto-occipital meningioma with visual hallucinations". Mooney AJ, Carey P, Ryan M, et al. *Am J Ophthalmol* 1965; 59:197-205.

"Epileptic facial metamorphopsia". Nass R, Sinha S, Solomon G. *Brain Dev* 1985;7:50-2.

"Metamorphopsia and palinopsia". Young WB, Heros DO, Ehrenberg BL, et al. *Arch Neurol* 1989;46:820-2.

"Micropsia and teleopsia limited to the temporal fields of vision". Bender M, Savitsky N. *Arch Ophthalmol* 1943;29:904-8.

"Apparent reduction in the size of one side of the face associated with a small retrosplenial haemorrhage". Ebata S, Ogawa M, Tanaka Y, et al. *J Neuro Neurosurg Psychiatry* 1991;54:68-70.

"A case of metamorphopsia caused by a very localized spotty infarct". Imai N, Nohira O, Miyata K, et al. *Clin Neurol* 1995;35:302-5.

"Selective deficit of visual size perception". Cohen L, Gray F, Meyrignac C, et al. *J Neurol Neurosurg Psychiatry* 1994;57:73-8.

Epstein, R. and Kanwisher, N. (1998) A Cortical Representation of the Local Visual Environment. *Nature*, 392, 598-601. <https://doi.org/10.1038/33402>

The Fusiform Face Area: A Module in Human Extrastriate Cortex Specialized for Face Perception Nancy Kanwisher, Josh McDermott, and Marvin M. Chun. *The Journal of Neuroscience*, June 1, 1997, 17(11):4302-4311

"The medial temporal lobe memory system". Squire, L. and Zola-Morgan, S. (1991). *Science*, 253, 1380-1386. doi:10.1126/science.1896849

"Pure Topographical Disorientation: A Definition and Anatomical Basis". M Habib, A Sirigu, *Cortex*, Volume 23, Issue 1, March 1987, Pages 73-85

["Electrical Stimulation of Human Fusiform Face-Selective Regions Distorts Face Perception". Josef Parvizi, Corentin Jacques, Brett L. Foster, Nathan Withoft, Vinitha Rangarajan, Kevin S. Weiner and Kalanit Grill-Spector. \*Journal of Neuroscience\* 24 October 2012, 32 \(43\) 14915-14920; DOI: <https://doi.org/10.1523/JNEUROSCI.2609-12.2012>](#)

["Electrical Stimulation of the Left and Right Human Fusiform Gyrus Causes Different Effects in Conscious Face Perception" Vinitha Rangarajan, Dora Hermes, Brett L. Foster, Kevin S. Weiner, X Corentin Jacques, Kalanit Grill-Spector, and Josef Parvizi, \*The Journal of Neuroscience\*, September 17, 2014, 34\(38\):12828 -12836](#)

["Understanding face perception by means of prosopagnosia and neuroimaging". Rossion B, \*Front Biosci \(Elite Ed\)\* 2014 Jun 1; 6\(2\):258-307. doi: 10.2741/E706.](#)



## Large Vessel Stroke as a Presenting Feature after COVID-19 Vaccination in a Young Adult

*Kwame Affram, M.D.<sup>1</sup>; Lena Ayari<sup>\*2</sup>; Marita John<sup>2</sup>; and Batool F. Kirmani, M.D.<sup>2,3</sup>*

1. Hospitalist Program, CHI St. Joseph Health, Bryan, TX; 2. Texas A&M University College of Medicine, Bryan, TX; 3. Endovascular Therapy & Interventional Stroke Program, Department of Neurology, CHI St. Joseph Health, Bryan, TX



### DISCLOSURE OF INTEREST

The authors report no conflict of interest.

### PATIENT CONSENT FOR PUBLICATION

The patient has given permission for this report to be published.

### ABSTRACT

Adenovirus-based COVID-19 vaccines from AstraZeneca and Johnson & Johnson have been associated with a syndrome of thrombosis, mainly involving the venous system, as well as thrombocytopenia akin to heparin-induced thrombocytopenia. Most of the cases were in women. Arterial thrombosis associated with these vaccines is relatively rare; however, a few cases have been reported with the AstraZeneca vaccine but not Johnson & Johnson. In this report, we present the rare case of a 24-year-old African American male who developed arterial thrombosis a week after receiving the Johnson & Johnson COVID-19 vaccination. He was brought to the emergency department due to altered mental status and symptoms of stroke including dysarthria, right facial droop, and right hemiparesis. A CT angiogram revealed thrombosis extending to his left middle cerebral artery, and this was confirmed with a brain MRI. He was admitted to the stroke unit, where aspirin and atorvastatin were administered. A thorough medical work-up, including a complete blood count and a coagulation panel, did not reveal any risk factors for clot formation. Fortunately, he recovered without sequelae and was discharged after two days. There have been several cases of blood clots linked to COVID-19 vaccination, leading to widespread vaccine hesitancy. In almost all the cases, thrombosis was associated with severe thrombocytopenia that resembled autoimmune heparin-induced thrombocytopenia. According to the currently accepted explanation, any adenovirus-vectored DNA vaccine can drive autoimmunity with autoantibodies to platelet factor 4 in a mechanism that is termed “vaccine-induced thrombotic thrombocytopenia”. However, in this unique case, the patient did not have thrombocytopenia, indicating that other unknown mechanisms could be at play. More data is required for a clearer picture of the incidence, distribution, and pathogenesis of stroke after COVID-19 vaccination so that appropriate recommendations and interventions can be put in place for optimal management.

**Keywords:** COVID; vaccines; cerebrovascular accident; thrombosis; thrombocytopenia

### INTRODUCTION

Thrombosis has been one of the adverse effects attributed to vaccination with some of the COVID-19 vaccines and this has led to vaccine hesitancy as well as potentially threatening widespread acceptance.<sup>1</sup> Thrombosis is mainly associated with adeno-associated virus based vaccines and has been widely reported with the AstraZeneca vaccine.<sup>2</sup> Recently, Ad26.COV2.S vaccines (Johnson & Johnson/Janssen), a recombinant adenovirus serotype 26 vector encoding the SARS-CoV-2 spike glycoprotein, have also been associated with thrombosis leading to revision in recommendations by the CDC.<sup>3,4</sup> In most of the cases, thrombosis was associated with severe thrombocytopenia and sometimes disseminated intravascular coagulation that resembled autoimmune heparin-induced thrombocytopenia.<sup>3,5</sup> According to Warkentin, Greinacher and colleagues, the vaccine-induced immune thrombotic thrombocytopenia was associated with IgG antibodies.<sup>6,7</sup> These antibodies recognize platelet factor 4, a chemokine protein released by activated platelets which activates platelets through their Fcγ receptors.<sup>6,8</sup> Here we report the development of a large vessel stroke in a young man with no predisposing factors a week after having had the Johnson & Johnson vaccine.

### CASE REPORT

A 24-year-old African American with a history of post-traumatic stress disorder was brought to the emergency department a week after his COVID-19 vaccination on account of mental status alteration. He was found down and rolling in his apartment leading to activation of the emergency medical services. His vitals at presentation were within normal limits and blood sugar was 99 mg/dl. He was confused, combative, and had dysarthria with a right facial droop. Besides testing positive for cannabinoids in his urine, his laboratory results including platelets were within normal limits (Table 1). Initial CT scan of his brain revealed no acute intracranial event (Fig.1A). However, CT angiogram of the brain was concerning for thrombosis in the terminal part of the left carotid artery and extending into A1 and M1 (Fig.1B). Follow up brain perfusion studies showed increased mean transition time in the distribution of M1 (Fig.1C) and a brain MRI confirmed an acute cerebral infarction on the left side (Fig.1D). He was admitted to the stroke unit and managed per protocol. Treatment was started with aspirin and atorvastatin. Neurosurgery was consulted; however, he did not meet the criteria for thrombectomy. He also did not receive TPA as he did not meet criteria given the extent of his lesion. Echocardiogram revealed no intramural



thrombosis. EKG and telemetry monitoring overnight did not reveal atrial fibrillation, flutter, or any other arrhythmia. A thrombophilia workup did not reveal any predisposition to clot formation (Table 1). Interestingly, his symptoms completely resolved within two days of admission and he was successfully discharged to follow up as an out-patient.

## DISCUSSION

The COVID-19 pandemic has inflicted a heavy burden of morbidity and mortality on populations worldwide. Fortunately, the introduction of vaccines against COVID-19 has brought hope for an end and reversion to pre-pandemic ways of life. While significant improvements in infection rates and hospitalizations are being realized, the development of vaccine-associated adverse effects may pose a threat to vaccine acceptance and could threaten gains made so far with vaccination.<sup>1</sup> Of the adverse effects of the vaccines, thrombosis appears to be one of the most alarming. The association between AstraZeneca and Johnson & Johnson COVID vaccines with thrombosis is small but concerning.<sup>3,4</sup> This was enough to warrant a temporary halt in distribution and revision of age and sex recommendations.<sup>3</sup>

Increased thrombosis due to adeno-associated virus based COVID-19 vaccines is usually associated with thrombocytopenia and occurs mainly in the veins of the brain and peripheral circulation.<sup>2,4,5</sup> However, reports of arterial thrombosis are relatively less common with a few cases having been reported for the AstraZeneca vaccine.<sup>9,10</sup> The mechanism of thrombosis is linked to platelet factor 4 antibody production akin to heparin-induced thrombocytopenia in almost all patients.<sup>7</sup> Interestingly, our patient did not have thrombocytopenia and thus we did not check for antibodies, as we did not suspect a heparin-induced thrombocytopenia-like process as has been discussed in most reports. A thrombophilia panel also did not reveal any predisposition to hypercoagulability in the patient (Table 1). Our patient's unique presentation of an isolated brain arterial thrombus in the absence of thrombocytopenia indicates other unknown mechanisms could be at play.

Demographic data indicate that females are more likely to develop thrombosis after Johnson & Johnson COVID-19 vaccination than males.<sup>5,6</sup> At this point, it is unclear whether the sexual differences are the same for both arterial and venous thrombosis as most of the reported data involves venous thrombosis. Trends on sex disparities in arterial thrombosis may become clearer with more data as the scale of vaccination expands. While sex disparities in venous thrombosis after Johnson & Johnson vaccination is quite apparent, data on racial differences are not that clear. However, it appears that white females make up the majority of the patients.<sup>6</sup> Our patient being a black male is therefore unique in the demographics of reported cases so far. This may reflect a possible low vaccination rate in the black male population or racial and sexual differences in prevalence and mechanism of thrombosis after vaccination.

**Table 1** Initial Laboratory Data

TEST	VALUE	REFERENCE RANGE
PT	13.4 sec	12.0-14.7
INR	1.0	
APTT	31.7 sec	22.9-36.1
White blood cells (WBC)	7.4 thou/uL	4.8-10.8
Red blood cells (RBC)	5.08 mill/uL	4.70-6.10
Hemoglobin (Hb)	15.7 g/dL	14.0-18.0
Hematocrit (Hct)	47.0%	42.0-52.0
Hexagonal Phase Neutralization	0.9 SEC	0-8.0
Protein C Chromogenic	82%	78-152
APC Resistance	2.8	2.2-3.5
Protein S Activity	108.0%	48-151
Functional Antithrombin III	104.0%	85-130
Factor V Leiden Mutation	Normal	
Factor VIII Activity	122.4%	56-157

**Figure 1** Patient brain imaging Data

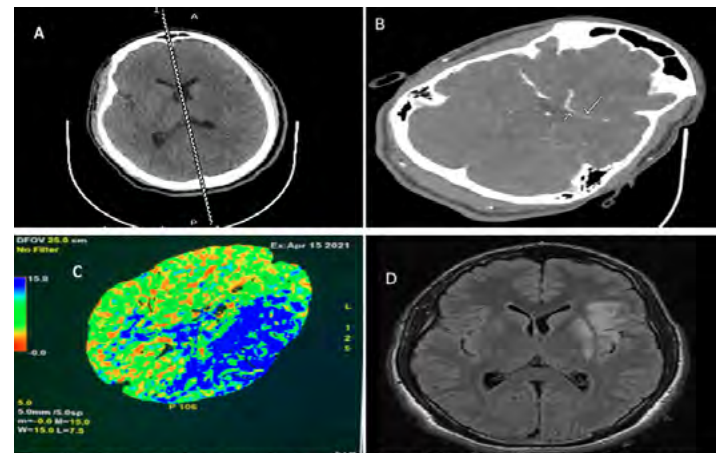


Fig 1. Patient brain imaging demonstrating a left sided infarct. A. CT slices of brain for imaging. No abnormality was shown on image analysis. B. CT angiogram demonstrating a thrombus in M1. C. MTT perfusion imaging showing reduced blood flow. D. MRI of the brain without contrast demonstrating an infarct in the left MCA distribution.

In conclusion, we present a rare case of a 24-year-old African American male who developed arterial thrombosis and ischemic stroke a week after receiving his COVID-19 vaccination. Given the rarity of a stroke at his age and his apparent lack of risk factors, it is quite likely that his stroke was due to increased coagulation due to the vaccine. The fact that he did not have heparin-induced thrombocytopenia-like features or a thrombogenic risk presents the possibility of alternative mechanisms to thrombosis due to the vaccine. His quick recovery could be attributed to his youth and possible reversibility of the pathogenic process. However, more data is required for a clearer picture on the incidence, distribution, and pathogenesis of stroke in young people after Johnson & Johnson vaccination so that appropriate recommendations and interventions can be put in place for optimal management.

## REFERENCES

Rosenbaum L. Escaping Catch-22 - Overcoming Covid Vaccine Hesitancy. *N Engl J Med.* 2021;384(14):1367-1371. doi:10.1056/NEJMms2101220

Wolf ME, Luz B, Niehaus L, Bhogal P, Bänzner H, Henkes H. Thrombocytopenia and Intracranial Venous Sinus Thrombosis after "COVID-19 Vaccine AstraZeneca" Exposure. *J Clin Med.* 2021;10(8):1599. doi:10.3390/jcm10081599

MacNeil JR, Su JR, Broder KR, et al. Updated Recommendations from the Advisory Committee on Immunization Practices for Use of the Janssen (Johnson & Johnson) COVID-19 Vaccine After Reports of Thrombosis

with Thrombocytopenia Syndrome Among Vaccine Recipients - United States, April 2021. *MMWR Morb Mortal Wkly Rep.* 2021;70(17):651-656. doi:10.15585/mmwr.mm7017e4

See I, Su JR, Lale A, et al. US Case Reports of Cerebral Venous Sinus Thrombosis With Thrombocytopenia After Ad26.COVS.2.S Vaccination, March 2 to April 21, 2021. *JAMA.* 2021;325(24):2448-2456. doi:10.1001/jama.2021.7517

Schultz NH, Sørvoll IH, Michelsen AE, et al. Thrombosis and Thrombocytopenia after ChAdOx1 nCoV-19 Vaccination. *N Engl J Med.* 2021;384(22):2124-2130. doi:10.1056/NEJMoa2104882

Greinacher A, Thiele T, Warkentin TE, Weisser K, Kyrle PA, Eichinger S. Thrombotic Thrombocytopenia after ChAdOx1 nCov-19 Vaccination. *N Engl J Med.* 2021;384(22):2092-2101. doi:10.1056/NEJMoa2104840

Warkentin TE. High-dose intravenous immunoglobulin for the treatment and prevention of heparin-induced thrombocytopenia: a review. *Expert Rev Hematol.* 2019;12(8):685-698. doi:10.1080/17474086.2019.1636645

Muir KL, Kallam A, Koepsell SA, Gundabolu K. Thrombotic Thrombocytopenia after Ad26.COVS.2.S Vaccination. *N Engl J Med.* 2021;384(20):1964-1965. doi:10.1056/NEJMmc2105869

Al-Mayhani T, Saber S, Stubbs MJ, et al. Ischaemic stroke as a presenting feature of ChAdOx1 nCoV-19 vaccine-induced immune thrombotic thrombocytopenia. *J Neurol Neurosurg Psychiatry.* 2021;92(11):1247-1248. doi:10.1136/jnnp-2021-326984

Blauenfeldt RA, Kristensen SR, Ernstsens SL, Kristensen CCH, Simonsen CZ, Hvas AM. Thrombocytopenia with acute ischemic stroke and bleeding in a patient newly vaccinated with an adenoviral vector-based COVID-19 vaccine. *J Thromb Haemost.* 2021;19(7):1771-1775. doi:10.1111/jth.15347



# Save the Date

TNS Women Neurologist  
Section Networking  
Happy Hour

Saturday, February 4, 2023  
6:30 – 7:30 pm

Hyatt Regency Austin (during Winter Conference)

**STAY CONNECTED AND ENTER TO WIN ONE OF OUR SOCIAL MEDIA GIVEAWAYS AT THE TNS WINTER CONFERENCE BY TAGGING TNS AND USING THE OFFICIAL EVENT HASHTAG: #TNSW2023.**



@TexasNeuros



@Texas\_Neuro





## Case Presentation

Sowsan Hafuth and Aziz Shaibani, MD

Nerve and Muscle Center of Texas, Houston

### HISTORY:

A 50 year old African American female presented with 4-month history of difficulty standing up and climbing stair. Within 2 months she started using a walker. She developed arms weakness and fatigue. She also reported diffuse muscle pain and swallowing difficulty for liquids and solids. She lost 20 pounds and developed dyspnea on exertion.

Past medical history was remarkable for hypertension and mild hyperlipidemia treated with diet.

Family history: she had 3 siblings and 3 children. No family history of neurological disease

### NEUROLOGICAL EXAMINATION

She uses a walker. She had symmetrical proximal weakness as follows: Deltoids: 4/5. Biceps 4+/5. The rest of the arms muscles: 5/5/ Iliopsoas muscles: 3/5. The rest of the bilateral leg muscles: 5/5. Neck extensors: 4+. No facial weakness or winging of the scapula were noted. Sensation and deep tendon reflexes were normal.

### LABORATORY FINDINGS

CPK level was 200 IU/L. ANA was negative. TSH was normal. HMGCR antibodies were negative. Serum protein electrophoresis revealed IgG kappa monoclonal gammopathy. Bone marrow aspiration was normal. Needle electromyography revealed 30% short duration polyphasic units in the proximal legs and arms muscles and 2+ fibs in these muscles and in the thoracic paraspinal muscles.

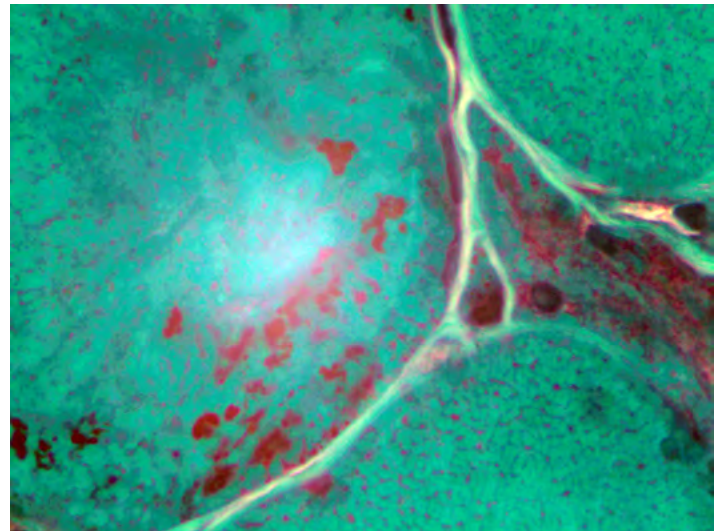
The following test is the most diagnostically useful:

- 1- MRI of the muscles
- 2- US of the muscles
- 3- Left biceps muscle biopsy.
- 4- Genetic testing for nemaline myopathy

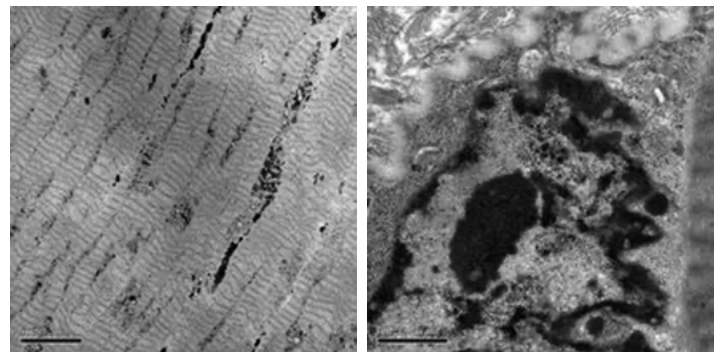
Left biceps muscle biopsy revealed:

- 1- Variation of fiber size
- 2- Many necrotic fibers
- 3- Several ragged red fibers
- 4- Rare endomysial inflammatory foci
- 5- Multiple small rods in 25% of the fibers seen in the trichrome stain. (Figure 1)
- 6- EM confirmed nemaline rods originating from the Z band with disarray of the myofibrillar structure. (Figures 2,3).

The following is the most likely diagnosis:



Modified Trichrome Gomori stain: 1000x. Nemaline rods.



EM photos in low and high magnification showing the nemaline rods and disarray of the myofibrillar structure.

- 1- Congenital myopathy due to ACTA1 mutation.
- 2- Sporadic late onset nemaline myopathy (SLONM)
- 3- Myofibrillar myopathy
- 4- Mitochondrial myopathy

### ANSWER:

This is a case of SLONM.

This is a rare and progressive myopathic disorder characterized by:

- 1- Mean age of onset is 52 years.
- 2- Subacute onset of usually symmetrical weakness of the proximal arms and legs muscles and myalgia.
- 3- Dysphagia and respiratory compromise are common leading to diagnostic confusion with acid maltase deficiency.

- 4- Creatinine Kinase is usually normal or slightly elevated,
- 5- 10-year survival is 68%.
- 6- 50% associated with MGUS mostly IgG Kappa or lambda, and those cases are more progressive.
- 7- Prednisone, intravenous gammaglobulin, chemotherapy, and autologous stem cell transplantation are usually effective.

## DIFFERENTIAL DIAGNOSIS

- 8- Autoimmune necrotizing myopathy which is also associated with progressive necrotizing myopathy, myalgia and dysphagia. However, CK is usually very high.

- 9- Myofibrillar myopathy is also characterized by progressive necrotizing myopathy and normal or mildly elevated CK but usually there is distal and cardiac involvement and myofibrillar changes in the muscle biopsy.
- 10- HIV nemaline rod myopathy is very similar to SLOM. HIV is to be tested in these cases in order to treat any underlying HIV infection.
- 11- hereditary nemaline rod myopathy is a congenital myopathy that is rarely seen in adult. Test for ACTA1 and other associated genes is important.

## REFERENCE:

SLOM, Nizar Chahin, et al. NEUROLOGY 2005;65:1158-1164



# TNS Legislative Advocacy Day

## Tuesday, April 4, 2023

at the Texas Capitol in Austin

The Texas Neurology Society will hold its first ever Legislative Advocacy Day at the Texas Capitol in Austin. The event will be held in conjunction with the Texas Medical Association's "First Tuesday" event and will give Texas neurologists a unique opportunity to meet with lawmakers face-to-face and discuss the policy issues that matter most to your practice and your patients.

**Wear your white coat!**

Register today at [texmed.org/FirstTuesdays](https://www.texmed.org/FirstTuesdays)



## New Onset Rare Para-Sagittal Seizures in the Setting of COVID Infection

Hannah Lichota\*, M.D.<sup>1,3</sup>; Cesar Carpio<sup>1</sup>;  
Sarah Momin<sup>1</sup>; Lena Ayari<sup>1</sup>; Batool Kirmani, M.D.<sup>1,2</sup>



1. Texas A&M University College of Medicine, College Station, TX; 2. Epilepsy and Functional Neurosurgery Program, Department of Neurology, CHI St. Joseph Health, Bryan, TX; 3. Rush University Medical Center, Chicago, IL

### ABSTRACT

Well into the third year of the SARS-CoV-2 pandemic, clusters of symptoms across organ systems are still being described. Many infected individuals experience mild respiratory symptoms, while others develop atypical pneumonia with progression to acute hypoxic respiratory failure. In addition to respiratory compromise, neurological effects of the virus contribute significantly to its morbidity and mortality<sup>3,23</sup>. Early landmark studies from Wuhan, China found that upwards of 36% of hospitalized patients with COVID-19 experienced neurologic manifestations of the disease, ranging from acute cerebrovascular accidents to impaired consciousness and muscular injury<sup>5,22</sup>. Since then, further studies have detailed other neurological symptoms: loss of smell and taste, agitation, confusion, seizures, and corticospinal tract signs such as enhanced tendon reflexes and clonus<sup>3</sup>. These occur with particular frequency when the burden of COVID-19 disease is severe enough to necessitate inpatient and intensive care stays<sup>4,22</sup>. As research into neurological effects of SARS-CoV-2 infection progresses, it is important to consider that infection may cause varied and atypical symptoms in susceptible patients.

**Keywords:** seizure; parasagittal; COVID; encephalopathy; hemiplegia

### INTRODUCTION

Here, we describe the case of a patient who presented with episodes of right sided episodic hemiparesis with encephalopathy in the presence of SARS-CoV-2 infection. An extensive and clinically appropriate workup was notable for new onset parasagittal seizures on EEG (Figure 1). Workup was otherwise negative for metastatic lesions, cerebrovascular accident, central nervous system infection, or paraneoplastic syndrome. We postulate a relationship between the timing of this patient's acute onset of parasagittal seizures and infection with COVID-19.

### CASE SUMMARY

This patient was a 79-year-old Caucasian female with a past medical history of breast cancer, treated in the distant past with a left mastectomy and radiation therapy. She presented to the hospital just one day after discharge from a prior prolonged hospital stay with altered mental status. Her previous hospital

stay was originally for stroke-like symptoms; after an extensive 16 day stay and a workup including multiple brain and head MRI scans and lumbar puncture, nothing was found that explained her original presentation. During that prior admission, workup for left arm weakness was unremarkable. Studies obtained at that time included a CT Head, MRI brain, MRI Spine, lumbar puncture with cerebrospinal fluid analysis (including cytology). This workup was revealing only for metastasis of disease to her spine and iliac bone, presumably from her primary breast cancer. An EEG performed during this visit was negative.

However, in the interval between this prior admission and the current admission, our patient's mental status continued to decline. Upon readmission for altered mentation, a CT head and brain MRI were repeated. These did not show brain metastasis, lesion, or acute intracranial abnormality. She became incoherent and would not respond to verbal commands and exhibited intermittent, episodic right sided stiffness and hemiplegia. At this time, the working differential diagnosis for her acute encephalopathy included infectious encephalitis, autoimmune encephalitis, or a paraneoplastic syndrome, such as stiff person syndrome. A paraneoplastic panel including amphiphysin Ab, S, AGNA-1, ANNA-1, 2 and 3, Neuronal V-G K+ channel Ab was drawn; this resulted negative. Specifically, the amphiphysin ab titer was <1:240. An EEG was performed which showed cortical irritability in the left frontocentral and parietooccipital regions as well as spikes emanating from the left parasagittal regions (Figure 1). These EEG findings were consistent with our patient's altered mental status and episodic right-sided stiffness. At this time, the patient was loaded with Keppra 1500mg IV and started on a maintenance dose of Keppra 1g IV Q12 to suppress cortical irritability; this regimen resulted in resolution of her symptoms and a return to her pre-hospital baseline. A third MRI brain was performed and without evidence of metastatic lesions or cortical enhancement, so the treatment team concluded that no structural lesion was responsible for her symptoms and seizures. Upon preparation for transfer to an outside facility, a nasal swab performed for SARS-CoV-2 returned positive. Notably, the patient did not exhibit respiratory symptoms and was febrile only once (Tmax 102.2°F).

Our patient's EEG findings were consistent with the clinical semiology of partial seizures, manifesting as episodic right sided focal neurological symptoms. These findings coincided

with the time of onset of COVID infection. With treatment, the patient's acute encephalopathy and seizures resolved. Notably, she did not exhibit any other symptoms consistent with COVID-19 infection. Following resolution of infection, an EEG was repeated twice, both of which revealed complete normalization with no epileptiform discharges seen.

## CASE DISCUSSION

This patient's positive EEG results in the absence of a focal lesion on MRI are consistent with partial seizures, and it is plausible to consider a correlation between this and the patient's positive COVID status. Cortical signaling changes have been described in encephalopathic, COVID-positive patients before, by means of T2/FLAIR MRI. Early on in the course of the pandemic, two multicenter studies based in China reported a 0.47-0.66% incidence of seizures in patients with SARS-CoV-2 infection<sup>5,8</sup>. New onset seizures are uncommon yet serious neurological complications of SARS-CoV-2 infection, with limited data in terms of clinical semiology and underlying etiologies in association with electroencephalographic and imaging findings. A thorough review of the current literature reveals other case studies describing seizures during SARS-CoV-2 infection, and it is clear that certain patients experience *de novo* seizures as the presenting symptom of COVID infection, much like ours did<sup>9-17,19,21,22</sup>. Neurologic compromise and seizures have been described as late complications of COVID infection in critically ill patients, but it is unclear whether this is due to direct central nervous system infection in all of these patients or not<sup>20,22</sup>.

Performing a full neurological investigation and considering a broad differential diagnosis including paraneoplastic syndrome, metabolic derangements, and infectious complications aided our team in treating our patient. She was already considered high risk for seizures and status epilepticus due to her critically ill condition, a status magnified by her positive test result for SARS-CoV-2<sup>18</sup>. With successful treatment of anticonvulsant administration and supportive care for COVID infection, she achieved full resolution of symptoms and returned to her normal functional baseline. As long as COVID-19 infection counts remain high in the general population, coexistence of other neurological conditions is a given. However, our case exemplifies that when physicians recognize an unexpected neurological finding in a COVID-positive patient, they must employ a low threshold for full neurological evaluation including, but not limited to, EEG and MRI evaluation. This is necessary given the state of the pandemic: due to the ubiquitous nature of the disease and the constantly growing body of knowledge, neurological manifestations of COVID-19 may be overlooked and under-researched<sup>6,18,24</sup>. We advise physicians to keep a low threshold for ordering an EEG and neurological evaluation for COVID-positive patients in the setting of unexpected neurological findings, as a seizure presentation may be subclinical, atypical, or may mimic other events.

## REFERENCES

- Collantes MEV, Espiritu AI, Sy MCC, et al. Neurological Manifestations in COVID-19 Infection: A Systematic Review and Meta-Analysis. *Can J Neurol Sci.* 2021 Jan;48(1):66-76. doi: 10.1017/cjn.2020.146. Epub 2020 Jul 15. PMID: 32665054; PMCID: PMC7492583.
- Garg RK, Paliwal VK, Gupta A. Encephalopathy in patients with COVID-19: A review. *J Med Virol.* 2021 Jan;93(1):206-222. doi: 10.1002/jmv.26207. Epub 2020 Jul 11. PMID: 32558956.
- Helms J, Kremer S, Merdji H, et al. Neurologic Features in Severe SARS-CoV-2 Infection. *N Engl J Med.* 2020 Jun 4;382(23):2268-2270. doi: 10.1056/NEJMc2008597. Epub 2020 Apr 15. PMID: 32294339; PMCID: PMC7179967.
- Heneka MT, Golenbock D, Latz E, et al. Immediate and long-term consequences of COVID-19 infections for the development of neurological disease. *Alzheimers Res Ther.* 2020 Jun 4;12(1):69. doi: 10.1186/s13195-020-00640-3. PMID: 32498691; PMCID: PMC7271826.
- Mao L, Jin H, Wang M, et al. Neurologic Manifestations of Hospitalized Patients With Coronavirus Disease 2019 in Wuhan, China. *JAMA Neurol.* 2020 Jun 1;77(6):683-690. doi: 10.1001/jamaneurol.2020.1127. PMID: 32275288; PMCID: PMC7149362.
- Needham EJ, Chou SH, Coles AJ, et al. Neurological Implications of COVID-19 Infections. *Neurocrit Care.* 2020 Jun;32(3):667-671. doi: 10.1007/s12028-020-00978-4. PMID: 32346843; PMCID: PMC7188454.
- Roberto KT, Espiritu AI, Fernandez MLL, et al. Electroencephalographic findings in COVID-19 patients: A systematic review. *Seizure.* 2020 Nov;82:17-22. doi: 10.1016/j.seizure.2020.09.007. Epub 2020 Sep 15. PMID: 32957032; PMCID: PMC7490625.
- Lu L, Xiong W, Liu D, et al. New onset acute symptomatic seizure and risk factors in coronavirus disease 2019: a retrospective multicenter study. *Epilepsia.* (2020) 61:e49-53. 10.1111/epi.16524
- Moriguchi T, Harii N, Goto J, Harada D, Sugawara H, Takamino J, et al. . A first case of meningitis/encephalitis associated with SARS-Coronavirus-2. *Int J Infect Dis.* (2020) 94:55-8. 10.1016/j.ijid.2020.03.062
- Sohal S, Mossammat M. COVID-19 presenting with seizures. *IDCases.* (2020) 20:e00782. 10.1016/j.idcr.2020.e00782
- Vollono C, Rollo E, Romozzi M, et al. Focal status epilepticus as unique clinical feature of COVID-19: a case report. *Seizure.* (2020) 78:109-12. 10.1016/j.seizure.2020.04.009
- Chen W, Toprani S, Werbaneth K, et al. Status epilepticus and other EEG findings in patients with COVID-19: a case series. *Seizure.* (2020) 48:198-200. 10.1016/j.seizure.2020.08.022
- Hepburn M, Mullaguri N, George, et al. . acute symptomatic seizures in critically ill Patients with COVID-19: is there an association? *Neurocrit Care.* (2020). 10.1007/s12028-020-01006-1
- Elgamasy S, Kamel MG, Ghozy S, et al. First case of focal epilepsy associated with SARS- coronavirus-2. *J Med Virol.* (2020) 92: 2238-42. 10.1002/jmv.26113
- Karimi N, Razavi AS, Rouhani N. Frequent convulsive seizures in an adult patient with COVID-19: a case report. *Iran Red Crescent Med J.* (2020) 22:e102828 10.5812/ircmj.102828
- Balloy G, Leclair-Visonneau L, Péréon Y, et al. Non-lesional status epilepticus in a patient with coronavirus disease 2019. *Clin Neurophysiol.* (2020) 131:2059-61. 10.1016/j.clinph.2020.05.005



17. Somani S, Pati S, Gaston T, Chitlangia A, et al. De novo status epilepticus in patients with COVID-19. *Ann Clin Transl Neurol.* (2020) 7:1240–4. 10.1002/acn3.51071

18. Tatum WO, Rubboli G, Kaplan PW, et al. Clinical utility of EEG in diagnosing and monitoring epilepsy in adults. *Clin Neurophysiol.* 2018 May;129(5):1056–1082. doi: 10.1016/j.clinph.2018.01.019. Epub 2018 Feb 1. PMID: 29483017.

19. Somani S, Pati S, Gaston T, et al. De Novo Status Epilepticus in patients with COVID-19. *Ann Clin Transl Neurol.* 2020;7(7):1240-1244. doi:10.1002/acn3.51071

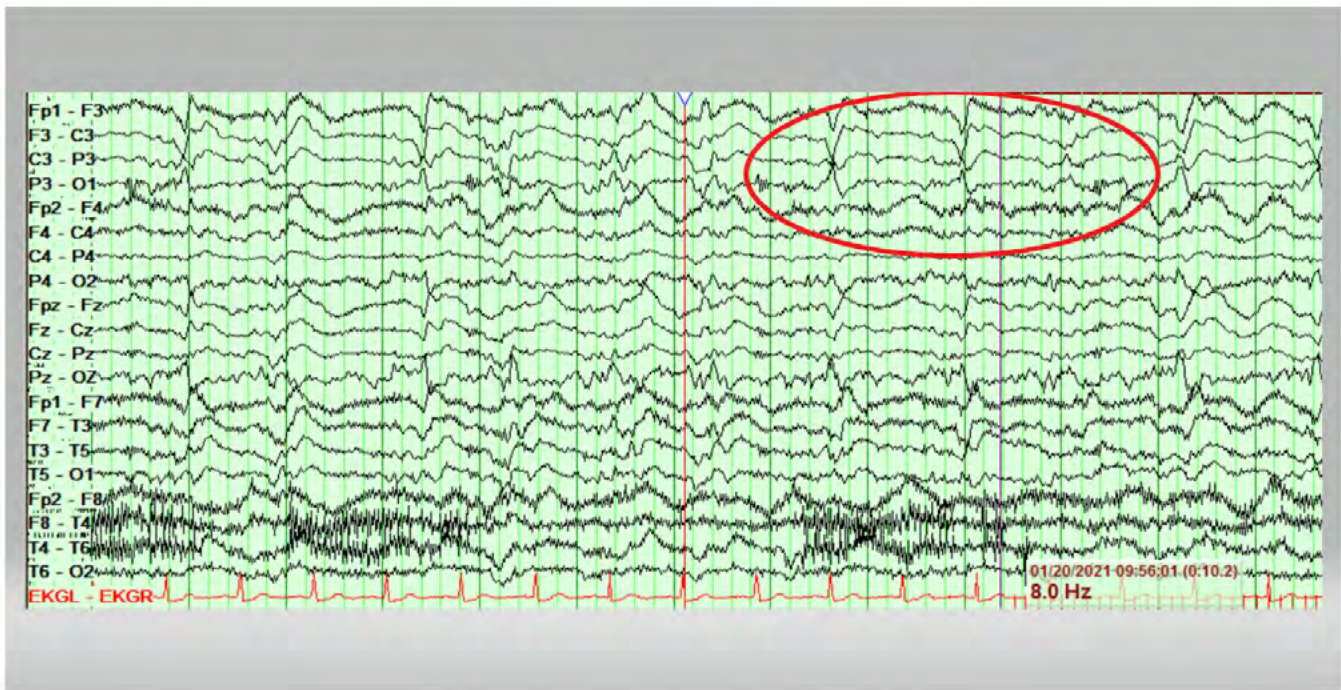20 Ashraf M, Sajed S. Seizures Related to Coronavirus Disease (COVID-19): Case Series and Literature Review. *Cureus.* 2020;12(7):e9378. Published 2020 Jul 24. doi:10.7759/cureus.9378

21. Emami A, Fadakar N, Akbari A, et al. Seizure in patients with COVID-19. *Neurol Sci.* 2020;41(11):3057-3061. doi:10.1007/s10072-020-04731-9

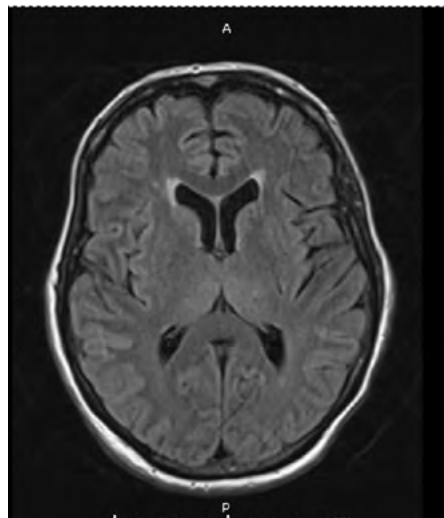
22. Fasano A, Cavallieri F, Canali E, et al. First motor seizure as presenting symptom of SARS- CoV-2 infection. *Neurol Sci.* 2020;41(7):1651-1653. doi:10.1007/s10072-020-04460-z

23. Finsterer J, Stollberger C. Update on the neurology of COVID-19. *J Med Virol.* 2020;92(11):2316-2318. doi:10.1002/jmv.26000

24. Louis S, Dhawan A, Newey C, et al. Continuous electroencephalography characteristics and acute symptomatic seizures in COVID-19 patients. *Clin Neurophysiol.* 2020;131(11):2651-2656. doi:10.1016/j.clinph.2020.08.003

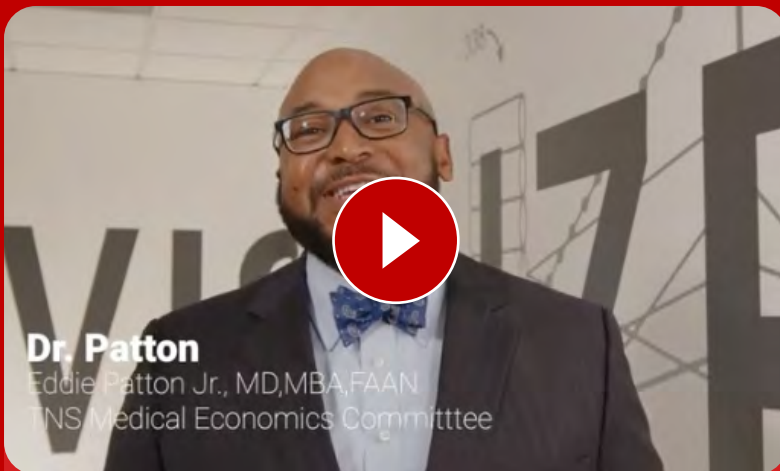

**Figure 1** EEG findings showing epileptiform discharges emanating from the left parasagittal region.



**Figure 2** T2 weighted MRI Brain w/o contrast, representative of an unremarkable scan with no hemorrhage, defect, focal lesion, metastasis, ventriculomegaly, or gray-white disruption noted.

## BUSINESS OF NEUROLOGY VIDEO SERIES



**Dr. Patton**

Eddie Patton Jr., MD, MBA, FAAN  
TNS Medical Economics Committee

### Business of Neurology Video Series

*2022 Videos include Alternative Practice Models,  
Are You Considering Selling Your Practice and  
Academic Careers in Neurology.*

- ✓ Need help with Coding?
- ✓ Employing APPs?
- ✓ How about Contract Negotiations?
- ✓ Enhancing your Practice with Ancillary Services?

*Check out the TNS website for more information or [click here](#)*

## Thank you to our Summer 2022 Conference Sponsors

### SILVER



### BRONZE



**Thank you TNS for  
supporting the  
“Hard Hats for Little  
Heads” program  
in 2022.**

*TMA Foundation*

For more information about the program,  
please email Ky Camero  
at [Ky.Camero@temed.org](mailto:Ky.Camero@temed.org)

### *Dues Reminder*

**Pay your TNS dues for 2023!**

Online at:

**[www.texasneurologist.org](http://www.texasneurologist.org)**

Or call: (512) 370-1532.

*Consider Auto Renewal to be notified before  
future dues payments are completed.*





# TNS COMMITTEES

**Women Neurologists Section** Come network at conferences! This section gets together one evening at the close of a day's general session for the purpose of connection, support and mentoring. It is the best time to meet fellow TNS women neurologists. Get involved today!

**Legislative Committee** More of how we practice neurology is determined at the Texas Capital and in Washington D.C. This committee fosters relationships with legislators and policy makers to education them about the delivery of neurologic healthcare to all Texans.

**Grants Committee** TNS gives back to its membership through the grants committee. Annually, committee members review submitted applications to determine which one/ones achieve the goal of improving and supporting neurological practices, education, and disease awareness and prevention. Continuing to further neurology is what this committee is designed to do.

**Communications Committee** Outreach is important! Did you know TNS has various social media platforms? Distributes a biannual newsletter? This committee works to develop materials/projects as well as contribute to the TNS website as they relate to TNS; grab the attention of the current and future membership. Join this committee as well as contribute to the TNS website and let your creative side shine.

**Medical Economics Committee** This committee serves as a forum to discuss topics encountered in everyday practices. Join and bring your concerns and/or accomplishments to the group. Assist in the brainstorming of topics for the "Business of Neurology" video series. Help TNS help its membership.

**Resident Committee** Do you want to shape a young neurologist's mind? Answer their questions about their future as a neurologist? Then, this is the committee for you! Join resident representatives from all of the Texas programs and some board members, too, as they work to develop projects or materials geared toward neurology residents. This committee also is responsible for the continuing development of the "Business of Medicine" program.

For more information, visit the [TNS Website](#).